

Local Anesthesia & Analgesia

Lyon Lee DVM PhD DACVA

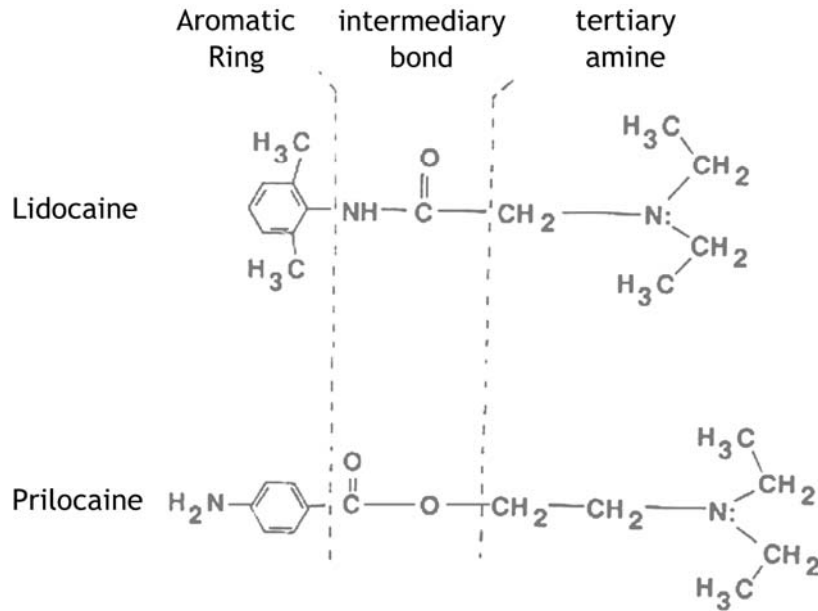
Introduction

- Several features of local anesthesia render it particularly useful in veterinary practice.
- Many surgical procedures can be carried out satisfactorily under local anesthesia (e.g., C-section in cows).
- Whether or not sedation is necessary as an adjunct will depend on the species, temperament and health of the animal, and on the magnitude of the procedure.
- In adult cattle, many operations are performed on standing animals and since sedation may induce the animal to lie down, it is better avoided. Enabling operation in standing animals also eliminates the dangers associated with forcible casting and restraint, and prolonged recumbency.
- In other animals, sedation is often employed to facilitate cooperation from animals by reducing fear and anxiety. The sedation also reduces the likelihood of sudden movement in animals.
- Preemptive local anesthesia in animals undergoing general anesthesia will reduce the amount of general anesthetic, minimizing the cardiopulmonary depression that may accompany and also leading to quicker recovery. It provides a useful pain relief, even beyond the full recovery from general anesthesia.
- In some situations with extremely depressed animals when they will tolerate, performing a surgical procedure under local anesthesia may be safer as well as more economical.
- The techniques are not difficult to learn and do not involve the use of expensive or complicated equipment.

Structure activity relationships

- Local anesthetics (LAs) consist of a lipophilic and a hydrophilic portion separated by a connecting hydrocarbon chain (see figure 1).
- An ester (-CO-) or an amide (-NHC-) bond links the hydrocarbon chain to the lipophilic aromatic ring.
- The hydrophilic group is usually a tertiary amine, such as diethylamine, whereas the lipophilic portion is usually an aromatic ring, such as para-aminobenzoic acid.
- The nature of this bond is the basis for classifying drugs that produce conduction blockade of nerve impulses as ester local anesthetics or amide local anesthetics.
- Some examples are;
 - o Esters: procaine, cocaine, chlorprocaine, and tetracaine.
 - o Amides: lidocaine, bupivacaine
- *Amides drugs have "i" in generic preifx before "caine". Exception is piperacaine, an ester drug.*

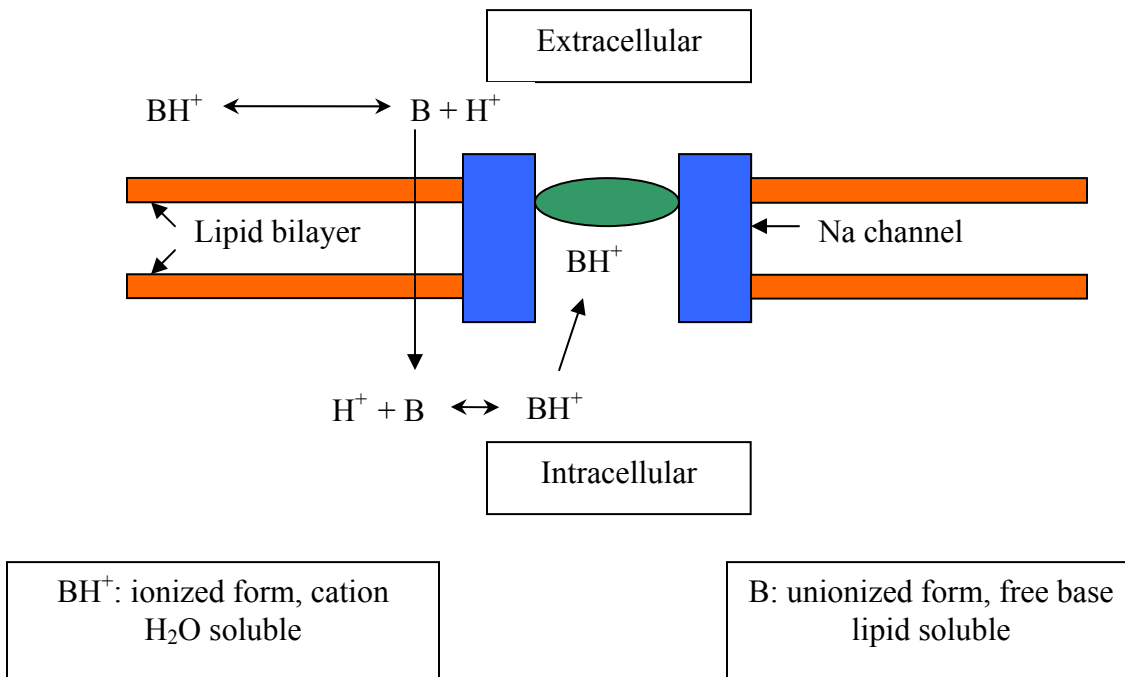
Figure 1. Chemical structure of local anesthetics.



Mechanism of action

- LAs block nerve conduction by inhibiting influx of sodium ions through ion-selective sodium channels in nerve membrane leading to impairment of the generation of action potential.
- The sodium channel itself is a specific receptor for local anesthetic molecules.

Figure 2. Mechanism of action of local anesthetics



Factors affecting onset, intensity, and duration of neural blockade

- Local anesthetics in solution exist in a chemical equilibrium between the basic uncharged form (B) and the charged cationic form (BH⁺).
- At a certain hydrogen concentration specific for each drug, the concentration of local anesthetic base is equal to the concentration of charged cation. This hydrogen concentration is called the pKa.
- This relationship is expressed as,

$$\text{pH} = \text{pKa} + \log \frac{[\text{B}]}{[\text{BH}^+]}$$

- Lower pKa means greater fraction of the molecules exist in the unionized form in the body, so more easily cross nerve membranes leading to faster onset.
- The pKa of currently used local anesthetic compounds lies between 7.7 and 8.5.
- The commercially available solutions are always acid so that they contain more ionized molecules.
- Acidosis in the environment into which the local anesthetic is injected (as is present in an infected, pus tissue) further increases the ionized fraction of drugs. This is consistent with slower onset and poor quality of local anesthesia when a local anesthetic is injected into an acidic infected area.
- Local anesthetics with a higher degree of protein binding have a prolonged duration of action. Increased dose increases the duration of the block.
- The half-life of esters is only a few minutes due to their rapid hydrolysis in the plasma and liver, whereas the half-life of amides is a few hours.
- Patients with reduced cholinesterase activity (new born, pregnant) may have an increased potential for toxicity from ester local anesthetics.
- Among the resulting metabolites from ester local anesthetics, the para-aminobenzoic acid is believed to be an antigen responsible for subsequent allergic reactions.
- Amides are mainly metabolized by the liver. Patient with severe hepatic disease may be more susceptible to adverse reactions from amide local anesthetics.
- Thin nerve fibers are more easily blocked than thick ones. However, myelinated fibers are more readily blocked than unmyelinated ones because of the need to produce blockade only at the node of Ranvier.
- In general, autonomic fibers (B and C fibers), small unmyelinated (C fibers), and small myelinated fibers (B and A δ fibers) will be more readily blocked than thick, myelinated fibers (A α and A β fibers).
- Thus, a differential block can be achieved where the smaller pain and autonomic fibers are blocked, while large touch and motor fibers are spared.
- This difference is due to the fact that nerve fibers containing myelin are relatively impervious to local anesthetic solutions compared to those which contain little or no myelin.
- The lipid solubility and pKa of the local anesthetic are the primary determinants of the degree of differential blockade.

Systemic and toxic effects of local anesthetics.

- Accidental intravenous injection of local anesthetics is the most common cause of adverse reaction associated with local anesthetic administration. In severe cases it can cause cardiac arrest.
- When the plasma concentration of LAs is excessive, sufficient cardiac sodium channels become blocked so that conduction and automaticity become adversely depressed. For example, excessive plasma concentration of Lidocaine may slow conduction of cardiac impulses through the heart, manifesting as increased PR interval and widened QRS complex on the ECG.
- Effects of LAs on calcium and potassium ion channels and local anesthetic induced inhibition of cyclic adenosine monophosphate (cAMP) production may also contribute to cardiac toxicity. Bupivacaine is more cardiotoxic than Lidocaine.
- **Always draw back on syringe to check not in vein before injecting local anesthetics.**
- General overdose depends on blood levels, therefore is influenced by total dose and speed of uptake from the tissues.
- As a very rough guide, the toxic dose of Lidocaine would be 8 mg/kg (much lower in the cat, 2mg/kg) and 4 mg/kg of Bupivacaine. (NB, in very small animals such as domestic cats, small dogs, goat kids, birds and small mammals this amount can be easily exceeded using solutions of standard concentration, so dilute it carefully and use with caution).
- Signs of overdose are initial sedation, followed with increasing dosage by twitching, convulsions, coma and death. Reports implicate prilocaine, benzocaine, lidocaine and procaine as causative agents to produce methemoglobinemia in some animals.

Clinically important points to recognize are:

- Spreading properties. Good spreading properties mean that specific nerve blocks need less accuracy.
- Speed of onset of action.
- Duration of action (and mechanisms limiting this, which include speed of removal from tissues and metabolism and removal from the body.).
- Effect on local blood vessels. Vasoconstriction (cocaine only) or vasodilation. (epinephrine is often added to cause vasoconstriction, thus delay removal and lengthen action).
- Local irritation and swelling (particularly important in horses)
- Toxicity.

Local anesthetics in common veterinary use

Lidocaine

- This is the most widely used general-purpose local anesthetic in veterinary use. It possesses reasonably rapid onset of action, with good spreading properties, being a good 'all round' useful local anesthetic.
- It may cause some local irritation and swelling, which is particularly a problem in the horse. It is available in a variety of concentrations or injection; with and without epinephrine; and in the form of solutions, creams, jellies, sprays etc.
- Duration of action is variable (depending on uptake) but will be around 1 hour without epinephrine, and 2 hours with epinephrine.

Bupivacaine

- This drug has a prolonged duration of action; up to eight hours when combined with epinephrine.
- It is therefore used whenever long action is required (post-op analgesia; prolonged surgery etc).

Mepivacaine

- This is the most widely used drug in the horse as it causes very little swelling and edema in the area of injection, possibly as it lacks vasodilatory action.
- Onset of action is faster and reliability of block greater than with prilocaine.

Prilocaine

- It has slower onset of action, and spreads less well compared to lidocaine.
- The unique ability of prilocaine to cause dose-dependent methemoglobinemia limits its clinical usefulness.
- The main use is in the horse as it causes less swelling but great accuracy is needed when doing specific nerve blocks.

Other local anesthetics

- Proparacaine is used to anesthetize the cornea of the eye. When dropped on the cornea it has a rapid onset of action (within 1 minute) and lasts for about 15-30 mins. It is nonirritant, and does not affect the size of the pupil.
- Amethocaine is well absorbed by surfaces and is used on mucous membranes.
- Procaine, an older drug with slow onset of action and poor spreading powers has been superseded by the more modern drugs.
- Cocaine the original local anesthetic is the only one to cause vasoconstriction. It is now not used as a local anesthetic because of its potential for abuse (Schedule II).
- Newer long acting local anesthetics with less cardiotoxicity, e.g., ropivacaine or levobupivacaine, are now available for man, but are currently very expensive for veterinary use.

Common methods of producing local anesthesia

- Surface (topical) anesthesia
- Intrasynovial anesthesia
- Infiltration anesthesia
- Spinal anesthesia
- Intravenous regional local anesthesia
- Regional anesthesia

Surface (topical) anesthesia

- This refers to the use of local anesthetics in solution sprays as well as in various creams and ointments, on mucous membranes; drops into the eye; sprays or brush in laryngeal area, infuse into the nostrils, urethra, or rectum.

Intrasynovial anesthesia

- In joints, bursa, and tendon sheaths.
- Useful for both diagnosis of lameness, and for general pain relief.
- The local anesthetic chosen must cause minimal irritation, and great care in sterility is necessary as infection in these sites occurs easily.

Infiltration anesthesia

- By this method the nerve endings are affected at the actual site of operation.
- Most minor surgery can be done this way, excluding surgery on teats in cattle or small animal digits.
- Problems occur through infection (never inject local analgesic through infected tissues), irritation, distortion of the wound, swelling and some delay in post-operative healing.
- A variation of infiltration anesthesia designed to minimize these effects is **field anesthesia**. Here, walls of anesthesia are made by infiltrating the tissues around (rather than at) the surgical site.
- Advantages include absence of distortion of the anatomical features in the line of incision; muscle relaxation and no interference to healing. An example of a field anesthesia technique which is widely used in cattle is the “Inverted L or 7 block” for anesthesia of the abdominal fossa.
- Ring blocks whereby the tissue all around a distal organ is infiltrated with local anesthetic, is another form of field anesthesia : examples of where this is used is on the teats of cattle (**do not use epinephrine here**, as vasoconstriction could lead to ischemic necrosis and sloughing of tissue) or around the limb of cattle.

Spinal anesthesia

- Spinal anesthesia is the injection of local anesthetic around the spinal cord.
- When local anesthetics such as lidocaine or bupivacaine are used, all the segmental nerves (sensory and motor) which pass through the anesthetic are paralyzed, although when opioids are used only sensory block occurs.
- Spinal anesthesia is divided into two types; ‘epidural’ and ‘true spinal’.
 - o Epidural (or extradural) anesthesia refers to depositing of local anesthetics into the extradural space. The needle enters the spinal canal, but does not penetrate the meninges. The anesthetic is therefore limited to the canal outside the dura mater.
 - o True spinal anesthesia refers to the **subarachnoid** access (usually known as ‘spinal’ anesthesia) in which the needle penetrates the dura mater, and the analgesic is injected into the cerebrospinal fluid (CSF).

Effects of subarachnoid and epidural anesthesia

- The requirements from these techniques is paralysis of sensory nerves to the area in which surgery is going to be performed.
- Muscle relaxation can be an added bonus or a disadvantage.
- Muscle relaxation of the limbs causes recumbency; and of the thoracic region limits respiratory movement.
- If local analgesic reaches the cervical region and affects the phrenic nerves, then respiration ceases!
- Thus most spinal and epidural anesthesia is injected in the caudal regions of the animal, although there are several variations in terminology used, generally where injection of drug is in the coccygeal region and the dose of drug is such that the hind limbs are not affected, it is termed “caudal anesthesia” where a higher dose of drug is given, still at the coccygeal area, so the hind limbs may be just affected, the term “epidural anesthesia” is used, and where the block extends to the abdominal region, either because of the volume used, or because the injection is carried out at the lumbosacral space, the term used is “anterior epidural”.

Autonomic effects of epidural anesthesia

- Many of the spinal nerves also carry fibers of the autonomic nervous system, which will also be blocked.
- Most important to the anesthetist are the sympathetic fibers, responsible for vasomotor tone. Thus spinal and epidural anesthesia always causes hypotension; and if the block is sufficiently anterior to block the splanchnic outflow, this hypotension can be severe, even life threatening.
- IV fluid line is essential prior to performing an epidural block to treat a potentially dangerous hypotension.

The area blocked by epidural anesthesia will depend on

- The site of injection. Common sites used in veterinary medicine (depending on the species) are the sacrococcygeal or intercoxygeal space, and the lumbosacral space. However, it is possible to carry out “segmental” blocks using other points of injection (widely used in man; development in veterinary use only just under way).
- Quantity, volume of and specific local anesthetic injected. (Well examined in man; in veterinary use work dates from 1940’s; no recent work with newer anesthetics).
- Size of the spinal canal. This varies not only between species of the same weight, but between breeds; with age; and with condition of the animal (e.g., fat/thin etc.).
- Position of animal (effects of gravity on spread).
- Removal of the anesthetic from the canal. Again this depends on multiple factors, including age (influences size of “holes” in the dura around the nerves), condition, blood flow etc. The use of vasoconstrictors (epinephrine) will delay removal.
- Thus epidural or spinal anesthesia is not a very precise technique, and it is difficult to estimate the extent of block which will occur, or its duration.

Dangers of spinal and epidural block

- Infection- Careful sterile precautions (**good clipping and scrubbing**)
- Irritation causing spinal damage (most likely with subarachnoid).
- Hindlimb motor paralysis (problem in large animals, acceptable in small).
- Hypotension - most likely with an anterior block. Where this is being done fluid therapy or inotropes should be available to maintain blood pressure.
- Respiratory paralysis (only if massive overdose of local analgesic used).

Epidural anesthesia in the Dog and Cat.

- The epidural injection site in dogs and cats is located at the lumbosacral junction between the seventh lumbar (L-7) and the first sacral vertebra (S-1).
- In dogs the spinal cord terminates at around 6/7th lumbar vertebrae. Anterior epidural anesthesia may therefore be safely and easily induced at the lumbosacral junction.
- In cats, (and small ruminants, cattle), however, the spinal cord terminates at the 3rd sacral vertebra (in ruminants, it is in S-1), and both the spinal cord and subarachnoid space are very close to the site of epidural injection.
- The spinal cord is supported, protected, and stabilized by vertebral column, ligaments and meninges.
- The epidural space is located immediately below the ligamentum flavum separating the dura mater from the vertebral periosteum, the lining of the spinal canal.
- To locate the site, identify the iliac prominences on either side, and take an imaginary line between them crossing the dorsal spinous process of the last lumbar segment.
- The site for the needle insertion is immediately caudal to this, in the midline.
- Restrain laterally or in sternal recumbency (personal preference). The hair over the lumbosacral junction should be clipped and aseptically prepared.
- Sterile surgical gloves should be worn during the procedure. A 20-22 gauge, 1.5-2.5 inch spinal needle may be used; depending on the size of the animal, a longer 3.5 inch spinal needle is used for obese and large animals.
- To reach the epidural space, the needle must be passed in a ventral direction through the skin, subcutaneous fat, supraspinous ligament, interspinous ligament and ligamentum flavum (yellow ligament).
- If the needle continues ventrally past the epidural space it will encounter the dura mater, arachnoid membrane, pia mater and finally, the spinal cord. The dura mater, arachnoid membrane and pia mater constitute the three meningeal membrane layers that protect the spinal cord.
- The dura mater, meaning “tough mother”, is the outermost meningeal layer. The arachnoid membrane, thin and avascular, lines the inner surface of the dura mater.
- The innermost membrane layer, the pia mater, closely approximates the spinal cord. This layer is a highly vascularized membrane through which all blood vessels pass to enter and leave the CNS. Cerebral spinal fluid (CSF) is located in the subarachnoid space, which separates the arachnoid membrane and the pia mater.
- To perform epidural anesthesia, the injection must be made only into the epidural space, between the ligamentum flavum and dura mater.
- Epidural injection should be differentiated from spinal (or intrathecal) injection, in which the anesthetic is injected into the subarachnoid space, between the arachnoid membrane and the pia mater (this is also where the myelogram is performed in the disc problem dogs).
- Anesthetic agents injected into the subarachnoid space (spinal injection) produce true spinal anesthesia because of the lack of protection provided by the dura mater and arachnoid meninges. Consequently, the volume of the anesthetic solution must be reduced by one third. Hypotension can be a major complication.
- This procedure should not be carried out unless there is an intravenous line in place so fluids or anti-hypotensives can be given promptly.
- The epidural space is identified by advancing the needle from an area of high resistance (ligamentum flavum) to an area of low resistance (epidural space).
- This is usually accomplished using the “hanging drop” or the “lack of resistance” technique during injection.
- For cranial laparotomies or hindlimb orthopedic procedures a dose of 0.1 mg/kg of morphine with/without 0.5% bupivacaine of approximately 1 ml per 10 Kg is required.

Epidural anesthetic techniques

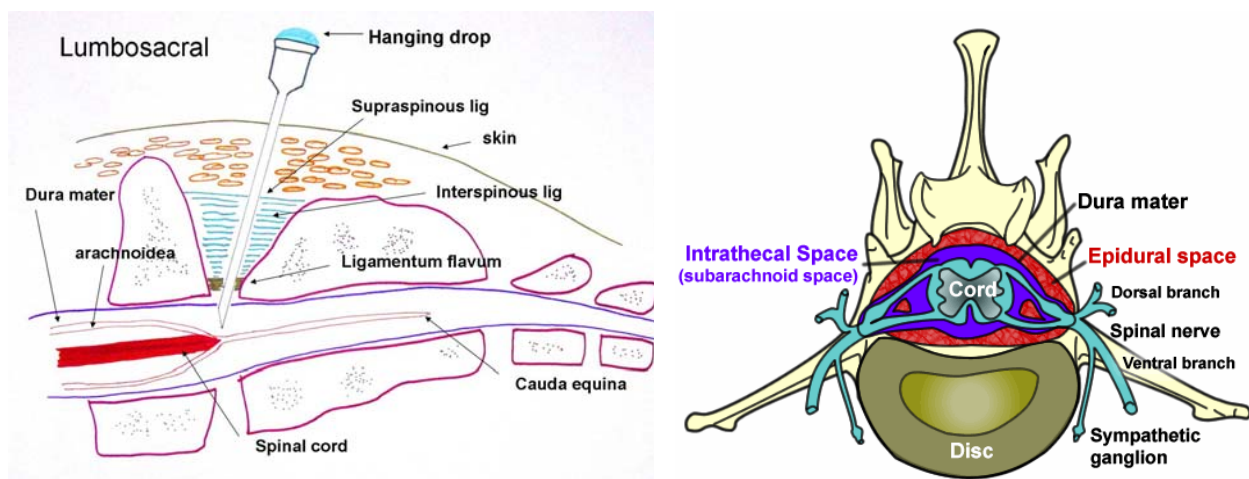
The “hanging drop” technique

- o This involves removing the stylet of the spinal needle, filling the hub of the needle with saline or anesthetic solution, and allowing one drop to hang from the hub.
- o As the needle is advanced through the ligamentous structures, the drop does not move.
- o However, upon penetration of the ligamentum flavum, the negative pressure in the epidural space will draw the drop of solution into the needle, indicating proper placement in the epidural space.
- o A “pop” felt through the needle is usually encountered when the spinal needle is passed through the ligamentum flavum.
- o The chance for a successful “hanging drop” technique is greater in large dogs than in smaller dogs and cats.
- o If the “hanging drop” technique fails, the “lack of resistance” technique can be used.

The “lack of resistance” technique

- o This indicates proper placement of the injection needle in the epidural space based on the amount of resistance to the injection of air or saline.
- o Once in the epidural space, the injection of air, saline, or anesthetic solution will encounter minimal resistance.
- o A separate syringe of normal saline (3 ml or air preferred by others) should be prepared for the “lack of resistance” technique.
- o When minimal resistance to the saline injection is encountered, the saline syringe is replaced with a syringe-containing anesthetic, and the injection is completed.
- o To rule out the possibility of administering drugs into the venous sinus (presence of the blood) or subarachnoid space (presence of CSF), it is important to aspirate or allow a few seconds to check bleeding before epidural injection.

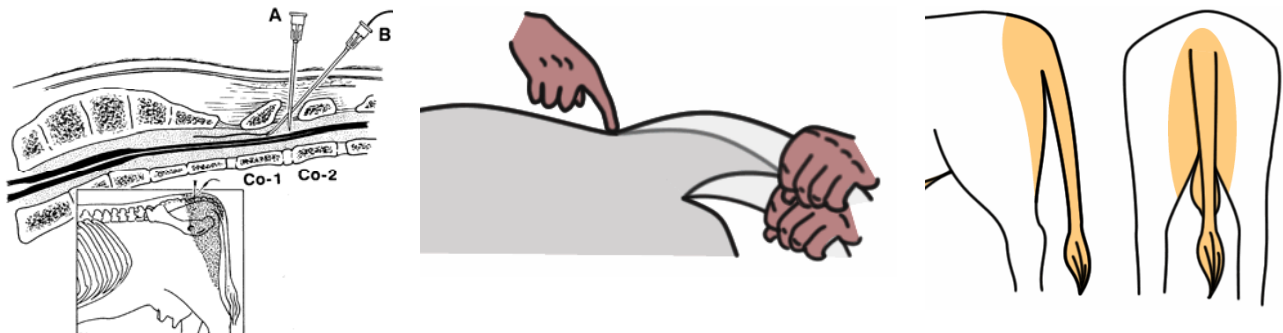Figure 4. Diagram showing various anatomic landmarks and positions of needles to perform epidural block technique.



Epidural anesthesia in bovine

- In the ox, the spinal cord ends in the region of the last lumbar vertebra, but the meningeal sac goes to the 3rd/4th sacral segments.
- For caudal and epidural anesthesia the injection site used is between coccygeal C1 and C2 (located by raising tail in “pump handle” fashion, the first obvious articulation behind the sacrum being C1 /C2).
- For a 500 kg bovine; 5-10 ml 2% lidocaine will give caudal anesthesia without causing hind limb ataxia or paralysis.
- Onset of paralysis of the tail should occur in 1-2 mins. The block will last 1-2 hours. Larger doses will produce increasingly anterior effects.
- By the time 100-150 mls 2% lidocaine is injected, the block will be sufficiently anterior to allow surgery of the hindlimbs, mammary tissue, flanks and abdominal wall.
- However, the bovine will be recumbent. Injection of local anesthetics can be carried out at the lumbosacral junction in order to produce an anterior block with less anesthetic.
- However, there is a danger of accidental subarachnoid injection. Segmental epidural anesthesia, where the anesthetic is injected into the epidural space at the region required can be used for analgesia of any ‘segment’ with less overall side effects. It is more difficult to perform; penetration of the meninges is likely, but in skilled hands it is a very useful technique.

Figure 5. Location of Sacral-Coccygeal/Intercoccygeal junction for the epidural injection in cattle. Note the tail can be lifted up and down to yield an indentation at the junction. The shaded areas show the blockage of the caudal-epidural following lidocaine injection. It induces both analgesia and motor blockade (From Thurmon et al. 1996)



Epidural anesthesia in the sheep and goat

- In both sheep and goats, anterior epidural anesthesia, induced by injection at the lumbosacral junction is easily performed and provides excellent analgesia and muscle relaxation for abdominal surgery.
- Recumbency may occur but is not a problem in these small animals. As in cattle, there is a risk of subarachnoid injection.

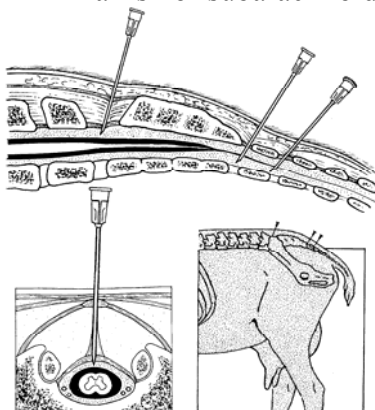


Figure 6. Diagrams to show various epidural blocking sites. lumbosacral space, sacrococcygeal, intercoccygeal. What determines the site depends on the area of operation and the technical competence (From Thurmon et al. 1996)

Epidural anesthesia in the horse

- Hind limb ataxia is a serious problem, so only caudal epidural techniques are used. These are useful for various obstetrical manipulations and surgery on the rectum, vagina and tail.
- The technique is less reliable than in cattle. Site of injection is usually sacrococcygeal junction but can be between C1 and C2. For 500 kg horse, a mixture of 50 mg of xylazine and 6 ml of 2% mepivacaine (may be repeated for another dose) may prove very effective.

Intravenous regional local anesthesia (Bier's block)

- In this technique, a limb vein is catheterized (see figure 7).
- The limb is then exsanguinated (Esmarchs bandage), and a tourniquet placed around the limb, at a pressure adequate to prevent arterial circulation (> 150 mmHg).
- Local anesthetic (preferably without epinephrine) is then injected into the vein.
- After a period of 15 minutes the area distal to the tourniquet is anesthetized until the tourniquet is removed.
- Potential problems are:
 - o Difficulty in finding the vein once the limb is exsanguinated (this is why it's best to have a catheter in place first).
 - o Cardiac arrhythmias or even arrest. This is due to an inadequate tourniquet (in man there have been more problems when bupivacaine was used than were found with lidocaine).
 - o Failure to take effect. Common reasons are inadequate tourniquet, inadequate time, and lack of exsanguination (it does work without exsanguination but not so well).
 - o Collapse when tourniquet is removed. This is because of anoxic waste products re-entering circulation. It is preferable if the animal is recumbent at this time.
 - o Damage as a result of the tourniquet being left on too long. This is rare. It can be left on for 1-1.5 hours on the limb of cattle and dogs.
- Intravenous regional anesthesia is commonly used in cattle for amputation of a digit.
- The diagrams below show some examples of veins available for injecting local anesthetics.
- The analgesic technique is particularly effective in the hind limb. For details of methods see Thurmon et al. 1996 pp 506-508.
- It is also used to a lesser extent for dogs to enable amputation of the digit combined with systemic sedation.

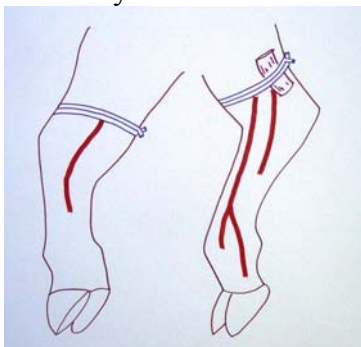


Figure 7. Easily recognized veins of the distal parts of the limbs in cattle. (1) Medial view of the right fore-limb A, radial vein; B, medial palmar digital vein. (2) Lateral view of the right hind-limb: C, lateral branch of lateral saphenous vein; D, lateral plantar vein; E, lateral plantar digital vein. (From Hall et al. 2000)

Regional anesthesia

- This term is used where specific nerves to the area concerned are blocked.
- Examples include specific nerve blocks to the limbs; paravertebral blocks; cornual block (for dehorning) and many others.
- A list of the blocks widely used in veterinary medicine, with suitable references, is given as below.

Paravertebral anesthesia

- Paravertebral anesthesia refers to the perineural injection of local anesthesia about the spinal nerves as they emerge from the vertebral canal through the intervertebral foraminae.
- The technique may theoretically be carried out in any species, and at any level of the spinal cord but in practice, its main use is to provide anesthesia of the lumbar region in ruminants.
- Its advantage is that it provides analgesia and muscle relaxation of the whole area covered by the segmental nerves blocked.
- Several different methods of achieving paravertebral anesthesia have been described.
- All methods approaching from the dorsal surface are equally effective.
- The method described whereby the needle is inserted ventral to the transverse processes of the spine has the disadvantage that the dorsal branches of the segmental nerves are not blocked, thus some skin sensitivity remains.
- Paravertebral anesthesia is easy to carry out, and almost always effective, except in the very large beef breeds where it may be very difficult to locate the necessary landmarks.
- A description of one method generally found to be effective for the cow is as follows;

Proximal paravertebral block (Farquharson, Hall, or Cambridge Technique)

- Indicated for standing laparotomy surgery such as C-section, rumenotomy, cecotomy, correction of gastrointestinal displacement, intestinal obstruction and volvulus.
- The dorsal aspect of the transverse processes of the last thoracic (T-13) and first and second lumbar (L-1 and L-2) vertebrae is the site for needle placement.
- The dorsal and ventral nerve roots of the last thoracic (T-13) and 1st and 2nd lumbar spinal nerves emerge from the intervertebral foramina are desensitized. 10-20 ml of 2% lidocaine is injected to each site onset occurs usually within 10 minutes of injection
- Analgesia of the skin, scoliosis toward the desensitized side - due to paralysis of the paravertebral muscles, increased skin temperature due to vasodilation (paralysis of cutaneous vasomotor nerves) indicates effective block. Duration of analgesia lasts approximately 90 minutes.

Distal paravertebral block (Magda, Cakala, or Cornell technique)

- Indicated for same as proximal paravertebral block above.
- The dorsal and ventral rami of the spinal nerves T13, L1 and L2 are desensitized at the distal ends of L-1, L-2 and L-4. A 7.5-cm, 18-gauge needle is inserted ventral to the tips of the respective transverse processes in cows where approximately 10-20 ml of a 2% lidocaine solution are injected in a fan-shaped infiltration pattern.
- The needle is completely withdrawn and reinserted dorsal to the transverse process, where the cutaneous branch of the dorsal rami is injected with about 5 ml of the analgesic.
- The procedure is repeated for the second and fourth lumbar transverse processes.
- 10-20 ml 2% lidocaine is used per site and onset and duration similar to proximal technique.

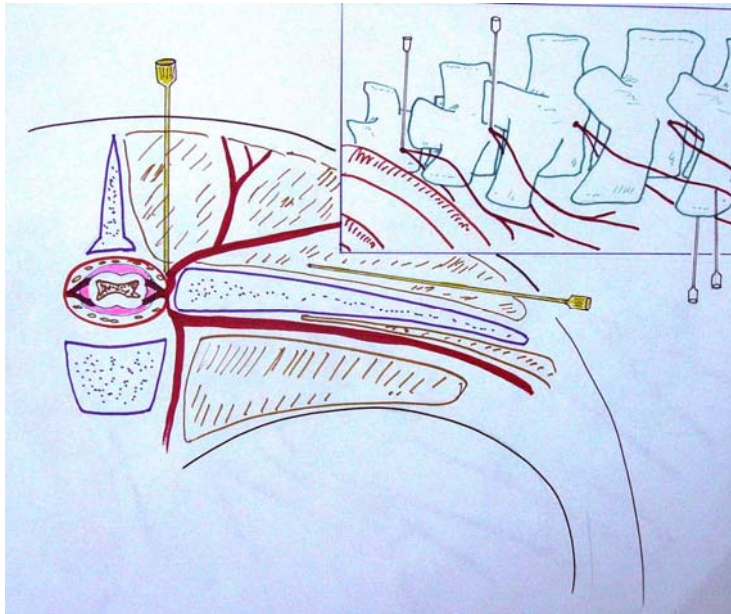
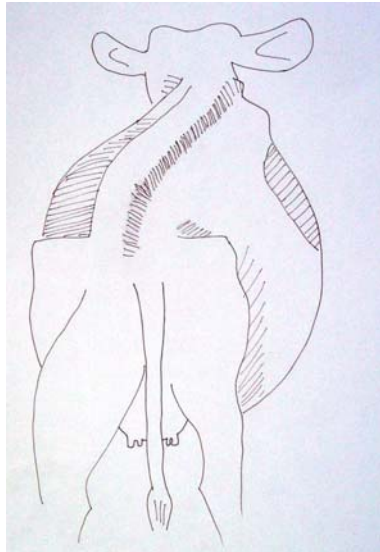


Figure 8. The proximal and distal paravertebral block at the T-13, L1 and L2 in cattle. This technique is one of the most commonly used regional analgesia in cattle for standing surgery (C-section, and laparotomy). (From Thurmon et al. 1996)



*Figure 9. Which side (left or right) of the cow is blocked with paravertebral technique?
Left side (the muscles are relaxed on the blocked side and the muscle tone remains at the unblocked side - right side - which pulled the cow toward this side and with adequate weight bearing) (From Hall et al. 2000)*

Table 1. Advantages and disadvantages of four common local anesthetic techniques in cattle.

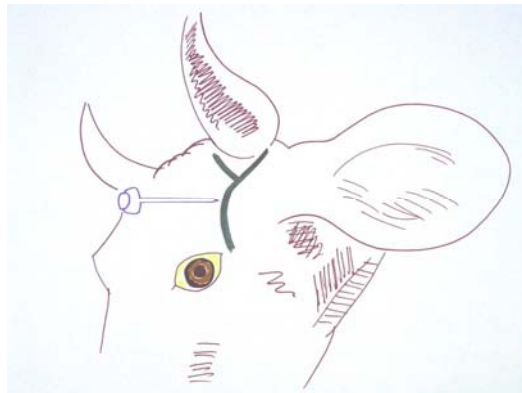
Techniques	Advantages	Disadvantages
Proximal Paravertebral Block	<ol style="list-style-type: none"> 1. Small dose of analgesic, 2. Wide and uniform area of analgesia and muscle relaxation, 3. Minimal intra-abdominal pressure 4. Increased intestinal tone and motility 5. Absence of local analgesic from the operative wound margins 	<ol style="list-style-type: none"> 1. Technical difficulty 2. Arching up of the spine due to paralysis of the back muscles. 3. Risk of penetrating vital structures such as the aorta and thoracic longitudinal vein on the left side and the caudal vena cava on the right side.
Distal Paravertebral Block	<ol style="list-style-type: none"> 1. The use of more routine size needles, no risk of penetrating a major blood vessel. 2. Lack of scoliosis minimal weakness in the pelvic limb and ataxia. 	<ol style="list-style-type: none"> 1. Larger doses of anesthetic are needed. 2. Variation in efficiency exists, particularly if the nerves vary in their anatomical pathway.
Infiltration Anesthesia	<ol style="list-style-type: none"> 1. Easiest and most commonly used 	<ol style="list-style-type: none"> 1. Edema and hematoma of the multiple injections along the incision site may interfere with healing 2. Incomplete analgesia and muscle relaxation of the deeper layers of the abdominal wall 3. Toxicity after injecting significant amounts of analgesic solution 4. Increased cost due to large doses and longer time required for injection
Inverted "L" or "7" Block	<ol style="list-style-type: none"> 1. Deposition of the analgesic away from the incision site, thus minimizing edema, hematoma, and possible interference with healing. 	<ol style="list-style-type: none"> 1. Incomplete analgesia and muscle relaxation of the deeper layers of the abdominal wall 2. Toxicity after injecting significant amounts of analgesic solution 3. Increased cost due to large doses and longer time required for injection

Local nerve blocks of the head

Cornual nerve block. Cattle.

- Indicated for dehorning and treating horn injury.
- Ophthalmic division of the fifth cranial nerve
- Injected on the upper third of the temporal ridge, about 2.5 cm below the base of the horn.
- The nerve is relatively superficial, about 0.7-1 cm deep. 3-5 ml of 2 % lidocaine is injected.
- Onset of analgesia occurs 10-15 minutes and duration of analgesia is approximately one hour.
- In adult cattle with well-developed horns, a ring block around the base of the horn may be necessary.

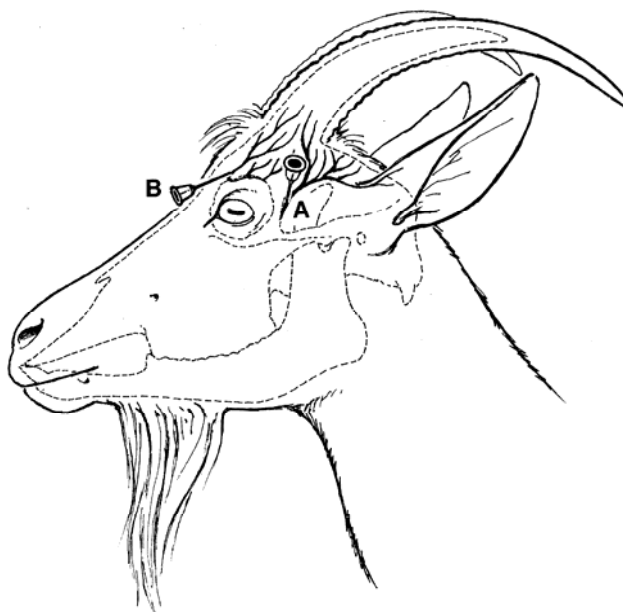Figure 10. Diagrams of needle placement sites for cornual nerve block in a cow. (From Hall et al. 2000)



Cornual nerve block. Goats.

- Again for dehorning, not as easy as in the cow as there are two branches of the nerve (lacrymal and infratrochlear branches).
- **Do not use in kids**, as tend to use a total overdose of local anesthetics in these very small animals.


Figure 11. Diagrams of needle placement sites for cornual nerve block in a goat. (From Thurmon et al 1996)



Auriculopalpebral block. Cattle and horses.

- Auriculopalpebral nerve supplies motor fiber to the orbicularis oculi muscle.
- It runs from the base of the ear along the facial crest, past and ventral of the eye, giving off its branches on the way
- The needle is inserted in front of the base of the ear at the end of the zygomatic arch and is introduced until its point lies at the dorsal border of the arch. 2% lidocaine 10-15 ml at injection site.
- Onset of analgesia occurs 10-15 minutes and duration of analgesia is approximately one hour. This block does not produce analgesia of the eye or the lids. In conjunction with topical analgesia (2% lidocaine), it is useful for the removal of foreign bodies from the cornea and conjunctival sac. Also used, but less frequently in other species.
- This block has no sensory effects but paralyzes the muscles of the eyelid. It is used to keep the eye open, for example, as an adjunct in ophthalmic surgery.
- This is one of the most commonly used techniques to block the motor function of the upper eye lid for ophthalmic surgery. To prevent eyelid closure during examination of the eyeball

Figure 12. Auriculopalpebral block in a cow and a horse (From Hall et al. 2000; Muir et al. 1999)



Retrobulbar nerve block. Cattle.

- Widely used in practice to enucleate the eye. May also be used in many other species.

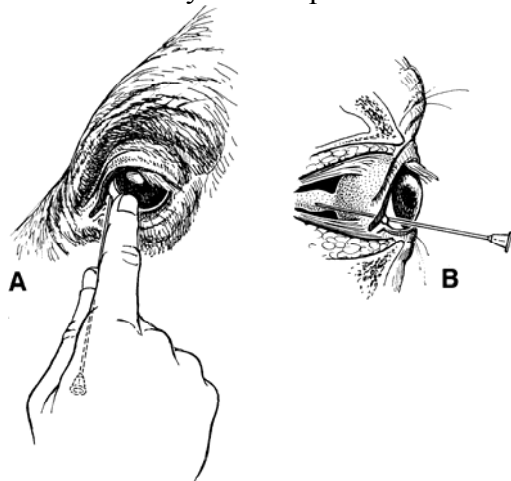


Figure 13. Retrobulbar needle placement through the medial canthus (A) to the orbital apex (B) (From Thurmon et al. 1996)

Peterson's eye block. Cattle.

- Requires more skill and specific anatomic knowledge than retrobulbar nerve block, but involves less risk in damaging surrounding anatomic structure around the eye globe, and less volume requirement reducing potential for systemic toxicity and expense.
- The point of injection is the notch formed by the supraorbital process cranially, the zygomatic arch ventrally, and the coronoid process of the mandible caudally.
- An one inch, 14 gauge needle is inserted through a desensitized skin as far anterior and ventral as possible in the notch.
- Insert a 4-5 inch, 18 gauge straight or slightly curved needle at the point of injection mentioned above in a horizontal and slightly posterior direction until it hits the coronoid process of the mandible.
- Gently manipulate the needle anteriorly until its point passes medially around the coronoid process, then advanced to the pterygopalatine fossa rostral to the solid bony plate that is in close proximity of the orbitotundum foramen. Following aspiration, 7 – 15 ml of local anesthetics are injected.
- Oculomotor, trochlear, abducens, and three branches of the trigeminal nerve (ophthalmic, maxillary, and mandible) are desensitized in 10 – 15 minutes following injection.

Facial nerves (Infraorbital, Mandibular, Mental and Supraorbital) - Dog/Horse.

- These nerve blocks may be used to allow surgery on the face. (Thurmon et al. 1996 pages 430-432, 449-450).

Anesthesia of the limbs

Horse.

- In the horse, very specific nerve blocks are used both for diagnoses of lameness and to allow surgery of the lower limb.
- Intra-articular injections are also used.
- Detailed information of the specific digital nerve block techniques is available in Thurmon et al. (1996) pages 452-460.

Cattle.

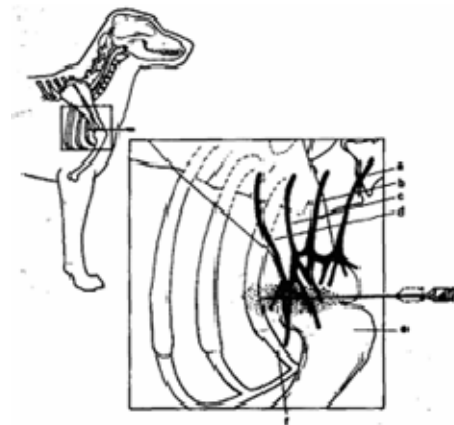
- The anatomy of the nerves to the limbs of cattle is very complicated. (Thurmon et al. pages 507-512).
- Although very specific nerve blocks may be used to desensitize the lower limb, it is more common to carry out the simpler.

Brachial plexus block

- Brachial plexus block is suitable for inducing analgesia for the surgery on the front limb, any area below distal part of humerus.
- The technique should be performed in a well-sedated or anesthetized animal.
- This block can be used in dogs, cats, small ruminants, calves, and foals.
- Brachial plexus block is relatively simple and safe to perform and produces selective anesthesia and relaxation of the limb and analgesia to the forelimb.
- This technique places a local anesthetic in close proximity to brachial plexus nerves that include the radial, ulnar, median, musculocutaneous and axillary nerves.
- The brachial plexus nerves derived from C-6, C-7, C-8 and T-1 spinal nerves roots.
- Gradual sensation and loss of motor function occurs within 10-30 minutes depending on the type of drugs used.
- Anesthesia lasts for approximately 2-6 hours, and total recovery requires approximately 6-9 hours.

Figure 14. Brachial plexus and nerve blocking technique.

- 7.5-cm, 20-22 gauge spinal needle is inserted medial to the shoulder joint and directed parallel to the vertebral column toward the costochondral junction.
- In larger size animal, if no blood is aspirated into the syringe as the needle is withdrawn, approximately 10-15 ml of 2% lidocaine or 0.5 % bupivacaine at 3 mg/kg with dilution up to 20-30 ml is slowly injected.
- Local anesthetics are injected to brachial plexus which would diffuse into the area to effect.
- Precise location is therefore usually less important than the spreading power of the drug and injected volume. a: C6, b: C7, c: C8, d: T1, f: first rib, e: Humerus. (From Thurmon et al. 1996)



Sources of reference

- Thurmon, Tranquilli and Benson Veterinary Anesthesia Williams and Wilkins 1996
- Hall, Clarke, and Trim Veterinary Anesthesia WB Saunders 2000
- Muir, Hubbel and Skarda A handbook of Anesthesia Mosby 1999