

## PRINCIPLES OF GI SURGERY

Eric Monnet, DVM, PhD, FAHA, DACVS, ECVS

## SURGERY

Gastrointestinal surgery is performed very commonly in small animals for biopsy, removal of a foreign body, upper gastrointestinal bleeding, resection of a necrotic segment of intestine, resection of necrotic portion of the stomach, and resection of a neoplasia. Approximately 10% of dogs with gastric dilatation volvulus have a devitalized gastric wall requiring gastrectomy. Ischemic injury occurs most commonly in the fundic area along the greater curvature. Upper gastrointestinal bleeding results from chronic renal and liver disease, mast cell tumor, gastrin producing neoplasia of the pancreas, gastric neoplasia, and non-steroidal anti-inflammatory drugs. Gastrotomy, gastrectomy, enterotomy, and enterectomy are the procedures routinely performed. General principles common to all of these procedures have to be followed.

### Antibiotic Prophylaxis

Gastrointestinal surgery is considered a clean-contaminated surgery. Therefore antibiotics are required during the procedures. The most common bacteria encountered during gastrointestinal surgery are *Escherichia coli*, *Enterococcus* spp, *Streptococcus*, *Staphylococcus aureus*, *proteus*, and *Bacteroides fragilis*. In the stomach the bacteria population is more limited than in the rest of the intestine because of the acid environment. In the colon the population of anaerobic bacteria is elevated. Before surgery the patient is placed on prophylactic intravenous antibiotic. For surgery of the stomach, ampicillin or first generation cephalosporin (20 mg/kg IV every 60 minutes) can be used. For the rest of the intestine, second generation antibiotics are preferable because they have a broad spectrum against gram + and -. Cefoxitin (20 mg / kg IV every 90 minutes) is the antibiotic of choice. A combination of ampicillin enrofloxacin can be used also. Antibiotics are interrupted at the end of the procedure unless the animal has peritonitis. The animal needs to be watch closely for signs of infection.

### Assessment of Viability

#### *Stomach*

No objective criteria exist to evaluate gastric wall viability. Absence of peristaltic wave, pale greenish to gray serosal color, thin gastric wall, and lack of bleeding after partial thickness incision are signs of gastric wall devitalization.

#### *Intestine*

Viability is assessed by coloration of the serosa, peristalsism, pulse in the jejunal arteries, and utilization of intravenous fluorescein. Fluorescein at the dose of 15 mg/kg is injected intravenously. Fluorescein emits a gold green fluorescence when exposed to ultraviolet light. Viable intestine has a smooth, uniform, green gold fluorescence. Hyperemic intestine has a brighter color than normal. Non-viable intestine has patchy fluorescence or no fluorescence. The fluorescence can also be located around blood vessels.

### Choice of Suture Material and Needles

A wide range of suture materials has been used during gastrointestinal surgery. It is recommended to use synthetic, absorbable monofilament suture materials. Synthetic sutures are stronger sutures than gut and more resistant to infection. Synthetic, absorbable sutures are absorbed primarily by hydrolysis, which is more predictable than enzymatic digestion. Monofilaments cannot harbor bacteria and do not have a wick effect like braided sutures; therefore they are resistant to infection. Polydioxanone (PDS), polyglyconate (Maxon), or Glycomer 631 (Biosyn) sizes 4.0 or 3.0 are the recommended sutures for gastrointestinal surgery. A taper needle is recommended for placement of sutures in the stomach wall and the intestine.

### Aspesis

Every effort should be made to prevent contamination of the abdominal cavity during gastrointestinal surgery. The stomach or the loop of intestine is “packed off” from the rest of the abdominal cavity. Layers of moist laparotomy sponges are used. Intestinal content is moved away for the surgical site with gentle manipulation, and atraumatic clamps are placed to prevent the intestinal content coming back. Stay sutures are placed in the stomach to elevate the stomach wall and prevent spillage of stomach content into the peritoneal cavity.

After completion of the surgery, the peritoneal cavity is lavaged with warm, sterile saline solution to remove gastrointestinal spillage and blood clots. Usually 1 liter of saline is used for a 10 kg dog. The entire fluid is eliminated with surgical suction to get the peritoneal cavity as dry as possible.

Gloves and instruments are then changed. New surgical towels are placed on the edges of the laparotomy. The abdominal cavity is then closed routinely.

## **Surgery of the Stomach**

### *Gastrotomy*

Gastrotomy incision is performed in a relatively avascular area, midway between the lesser and the greater curvature of the stomach. One stay suture is placed at each end of the planed gastrotomy incision. Stay sutures are used to manipulate the stomach and bring the stomach wall to the edge of the abdominal incision. The stomach is walled off with moist laparotomy sponges to prevent contamination of the abdominal cavity with gastric content. An 11 blade is used to stab the gastric wall next to one stay suture. Then a Metzenbaum scissors is used to extend the gastrotomy incision. The incision should be long enough to remove the foreign body without tearing the stomach wall. Hemorrhage occurs mainly in the seromuscular layer and can be controlled by ligation with fine absorbable sutures. The foreign body is extracted and the gastrotomy closed. Gastrotomy is closed with a one-layer, simple apposition pattern with 3-0 monofilament absorbable suture. The abdominal cavity is lavaged with warm saline prior to closure. Surgical gloves are changed and a new pack of instruments is then used to complete the abdominal closure.

Electrolyte and acid-base imbalances are corrected by intravenous electrolyte solution. Fluid therapy is maintained until oral fluid intake is adequate. Water is offered 12 to 24 hours after recovery from anesthesia. If the patient is not vomiting, then a small amount of bland diet can be offered. The amount of food is gradually increased over the next 4 days. Peritonitis after gastrotomy is a rare complication. Gastritis requires treatment with cimetidine or ranitidine and sucralfate.

### *Gastrectomy*

Gastrectomy is required to resect the necrotic stomach wall during GDV. Stomach wall resection after rupture of a gastric ulcer requires a wide margin since gastric ulceration could be associated with gastric adenocarcinoma or gastric lymphoma.

Two options are available: gastrectomy with traditional suture technique or stapling suture. Gastrectomy with automatic stapling equipment is associated with the best postsurgical outcome during GDV. This is the recommended technique.

### ***Gastrectomy During GDV***

Branches of the short gastric arteries and left gastro-epiploic artery supplying the area to be resected are ligated. Necrotic gastric wall is resected with Metzenbaum scissors to the level of healthy gastric tissue. A 2-layer closure with inverting pattern using 3-0 absorbable monofilament suture is necessary to close the stomach. This technique is associated with 60% mortality. If autostapling equipment is available, a Thoraco-Abdominal device (TA 55 or 90) can be used to perform the gastrectomy (Figure 1). The TA 55 or 90 is placed 2 staggered rows of staples respectively 55 or 90 mm long. The length of staples for stomach wall resection should be 4.8 mm. The TA 55 or 90 is first clamped on healthy stomach wall. The 2 rows of staples are then fired and a 15 blade is used to resect the devitalized stomach wall. The TA is then released. The suture line is then inspected to be sure that all the staples are in correct position and then a simple inverting suture line is applied. The advantages of this technique include decreased surgical time and decreased abdominal contamination from gastric spillage. Mortality rate with the autostapling equipment is close to 10%. Stomach rupture at the time of surgery is associated with severe peritonitis.

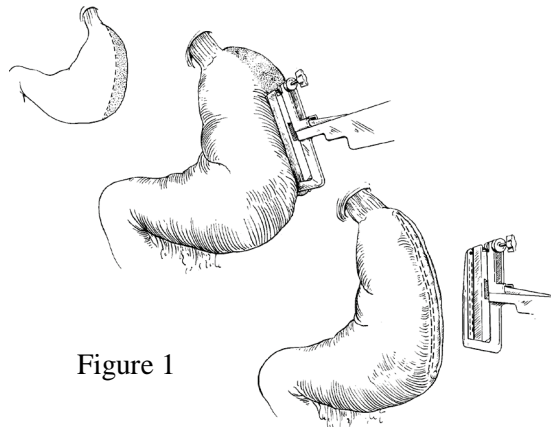


Figure 1

### ***Gastrectomy for Ulcer or Mass***

After identification of the stomach ulcer or tumor, the healthy stomach is retracted with stay sutures to prevent gastric spillage. The stomach wall is then resected around the lesion. The stomach wall is highly vascular. Bleeding blood vessels on the line of incision are ligated with 4.0 monofilament absorbable sutures. Staples can be used to close the gastrectomy. Hand suture can be performed if stapling equipment is not available. Two inverting continuous sutures are used to close the stomach after gastrectomy. A Cushing suture followed by a Lembert is the traditional technique. However, one simple, continuous apposition suture can be used to close the stomach.

Electrolyte and acid-base imbalances are corrected by intravenous electrolyte solution. Fluid therapy is maintained until oral fluid intake is adequate. Water is offered 12 to 24 hours after recovery from anesthesia. If the patient is not vomiting, then a small amount of bland diet can be offered. The amount of food is gradually increased over the next 4 days. Peritonitis after gastrotomy is a rare complication. Gastritis requires treatment with cimetidine or ranitidine and sucralfate.

### **Surgery of the Intestine**

#### ***Enterotomy***

A variety of foreign bodies can be ingested by young animals. Linear foreign bodies are more common in cats. Once an object has passed through the pylorus, the next smallest lumen are the distal duodenum and the proximal jejunum.

Plication of the intestinal wall indicates the presence of a linear foreign body. Usually one end of the linear body is still located in the stomach and needs to be released first. Particular attention is paid to the mesenteric border especially with linear foreign material. A linear foreign body can cut through the mesenteric border and induce leakage of intestinal content. Multiple enterotomies may be required to remove the entire linear foreign body. Enterectomy is required if the mesenteric border has been damaged.

Enterotomy is performed immediately distal to the foreign material. Intestine is walled off the abdominal cavity to prevent leakage of intestinal content inside the abdominal cavity. The incision on the antimesenteric border should be long enough to extract the foreign body without tearing the intestine.

The enterotomy is then closed with a simple interrupted appositional pattern with 4-0 monofilament absorbable suture. Since the submucosa is the only holding layer, it needs to be incorporated in the suture. The submucosa tends to retract away from the edge of the incision. The everted mucosa can be trimmed away to allow better exposure of the submucosa.

A serosal patch can be performed to improve blood supply to the enterotomy site and increase its tensile strength. The abdominal cavity is lavaged with warm saline prior to closure. Surgical gloves are changed and a new pack of instruments is then used to complete the abdominal closure.

#### ***Enterectomy***

An enterectomy is indicated if the intestine is not viable (intussusception, volvulus) or perforated by a linear foreign material at the mesenteric border, or if an intestinal neoplasia is present. End to end anastomosis is the preferred technique to perform an enterectomy. Intestine is walled off the abdominal cavity to prevent leakage of intestinal content inside the abdominal cavity. Enterectomy requires double ligation of the branches of the arterio-venous supply of the portion of intestine to resect (Figure 2).

The terminal arcade is also double ligated. Transection is performed between the double ligations. Crushing clamps are then placed on the portion of intestine that is going to be resected. The clamps are either placed perpendicular or at a slight angle toward the normal intestine. Non-crushing clamps are placed on the normal intestine 4 to 5 cm away from the enterectomy site after milking away the intestinal content. The intestine is transected with a scalpel blade

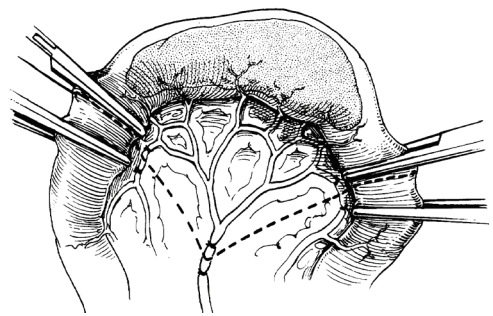


Figure 2

using the crushing clamps as a guide. Since the submucosa is the only holding layer, it needs to be incorporated in the suture. The submucosa tends to retract away from the edge of the incision. The everted mucosa can be trimmed away to allow better exposure of the submucosa (Figure 3) Anastomosis is performed with a simple interrupted or continuous appositional pattern with 4-0 monofilament absorbable suture (Figure 4).

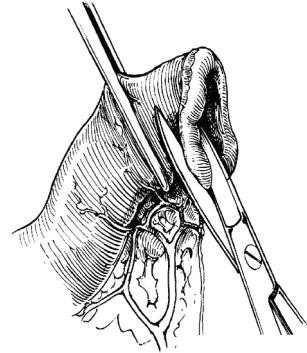


Figure 3

If the 2 extremities of the intestine are not of equivalent diameter, the smaller-diameter segment is incised on the antimesenteric border to create a larger spatulated edge (Figure 4). A serosal patch can be placed around the enterectomy site to improve blood supply and tensile strength.

The abdominal cavity is lavaged with warm saline prior to closure. Surgical gloves are changed and a new pack of instruments is then used to complete the abdominal closure.

Electrolyte and acid-base imbalances are corrected by intravenous electrolyte solution. Fluid therapy is maintained until oral fluid intake is adequate. Water is offered 24 to 48 hours after recovery from anesthesia. If the patient is not vomiting, then a small amount of bland diet can be offered. The amount of food is gradually increased over the next 4 days. Peritonitis after intestinal surgery is possible especially after removal of a linear foreign body. Patients should be closely monitored for signs of peritonitis for at least 3 days after surgery. Dehiscence of the intestinal anastomosis is the most common 3 days after surgery.

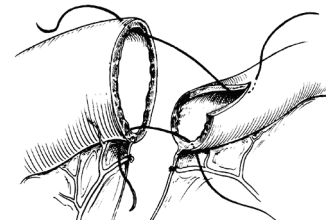
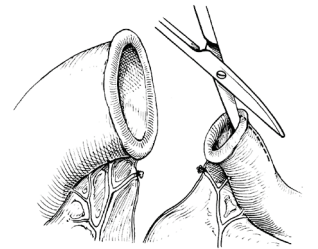


Figure 4

### Postoperative Monitoring

Postoperatively the patient should be monitored for signs of peritonitis, hypotension, disseminated intravascular coagulation, and pain. Leakage after gastrointestinal surgery can happen within 24 hours of surgery if the suture technique was not correct or 3 to 4 days after surgery at the peak of the debridement phase. Clinical signs of peritonitis will be tachycardia, tachypnea, acute abdominal pain, hypoglycemia, and hyperthermia. An abdominocentesis is then required to confirm the presence of bacteria in the abdomen. If bacteria are presented past 8 hours after surgery, the anastomosis is leaking and a second surgery is required.