

Clinical Approach to the Pruritic Cat

Dr Robert Hilton *BVSc(Hons) MACVSc CertVD MRCVS*

When dealing with cats with skin disease, it is important to understand that cats are not small dogs. The same cause may elicit different reaction patterns in different cats. Cats were worshipped as gods in ancient Egypt, and have not quite got over the fact. They are often difficult to pill, resent bathing, fail to eat elimination diets, hunt and steal food and love to remove topical medication by licking as soon as it is put on.

The principal causes of feline pruritus are listed below:

Common

Allergies and ectoparasites

- Flea bite allergy
- Food allergy (and on rare occasions, non immune-mediated adverse food) reactions
- Atopic dermatitis
- Mosquito hypersensitivity
- Reactions to mites (*Otodectes*, *Cheyletiella*, *Notoedres*, *Sarcoptes*)

Infections

- Bacterial pyoderma (almost always secondary)
- Dermatophytosis
- Feline Herpes infection (especially nose and face)
- Malassezia (especially Rex and Sphinx)

Less Common

Ectoparasites

- Feline demodicosis (The contagious short-bodied *D. gatoi* is commonly recognised in Europe and North America)
- Lice
- Infestation with *Trombicula* spp

Immune mediated disease

- Pemphigus foliaceus
- Drug reactions
- Sebaceous adenitis
- Lymphocytic mural folliculitis

Neoplasia

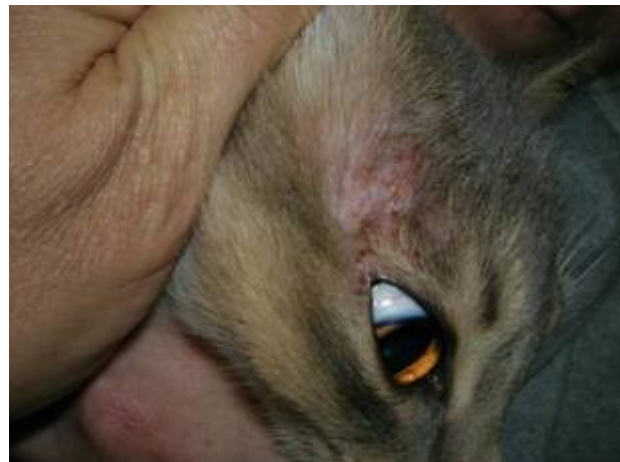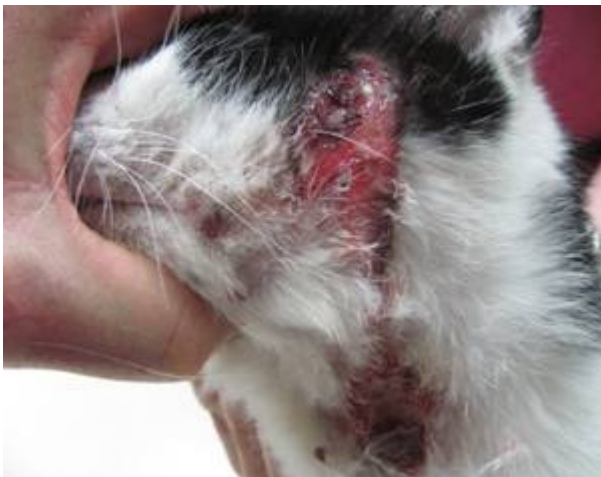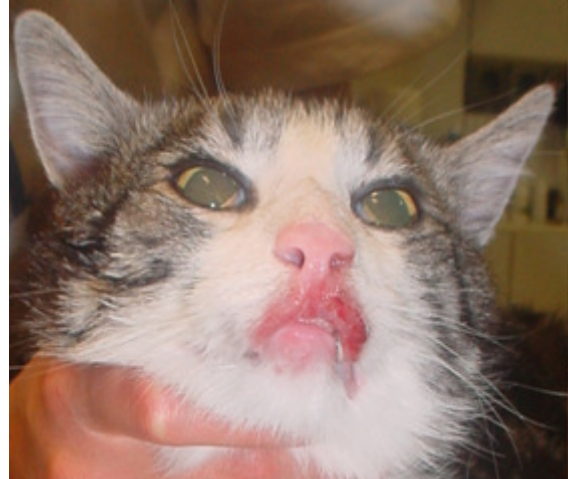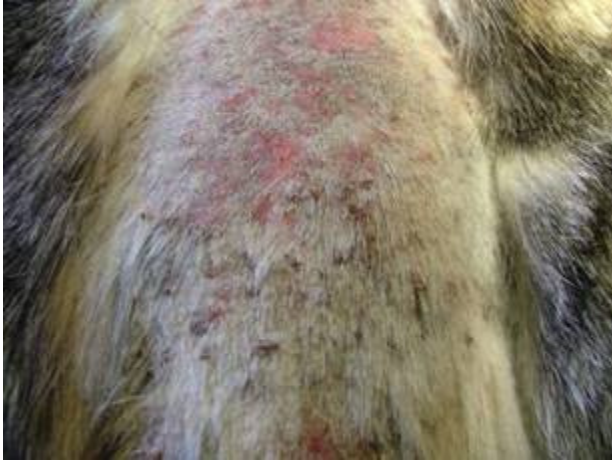- Epitheliotropic lymphoma
- Squamous cell carcinoma (common neoplasm, uncommonly pruritic)

- Feline mast cell tumours

Idiopathic

- Psychological pruritus
- Idiopathic facial dermatitis (dirty face disease) of Persian cats

(Adapted from Noli and Scarampella (2004))



Same aetiology
Same protocol
Same treatment

Manifestations of feline allergic disease. Any one or more of the following:

Milliary dermatitis
Eosinophilic granuloma
Over grooming syndrome
Urticaria pigmentosa

Eosinophilic plaque
Linear plaque/granuloma
Head and neck pruritus
Rodent ulcer

Milliary dermatitis presents as multiple small crusted papules on any part of the body. Eosinophilic plaque may be the result of coalescence of these papules into red eroded hairless raised lesions. Eosinophilic granuloma is a nodular lesion that needs to be differentiated from an infectious granuloma or a neoplasm. Urticaria pigmentosa is a mast cell rich nodular lesion identified in Sphinx and Rex cats.

In cats, it is particularly important to realise that dermatophytosis (ringworm) can be a pruritic disease and that every pruritic cat should be checked by toothbrush culture. A negative Wood's light examination does not rule out dermatophytosis as only 50% of *Microsporum canis* strains will fluoresce.

Psychological pruritus is a vastly over diagnosed disease, and in the author's experience, is uncommon. There is a history of stress in the life almost every cat. A recent study from a behaviour and dermatology referral practice has shown that the majority of cats referred for behavioural or psychodermatitis were fact suffering from a more common dermatological disease. A diagnosis of psychodermatitis should only be made after all dermatological causes have been eliminated and a lack of response to a therapeutic trial of corticosteroids (prednisolone 2 mg per kilogram daily for 10 to 14 days).

Pemphigus foliaceus in cats is certainly uncommon but by no means rare. The presence of yellow crusts particularly on the medial pinna and/or cheesy exudate in the nail beds raises the suspicion of pemphigus foliaceus. The presence of acantholytic cells on cytology and typical histopathology confirms the diagnosis.

Herpes virus dermatitis typically involves the nasal plan and/or facial areas. The diagnosis of herpes virus dermatitis can be quite difficult because on histopathology inclusion bodies are not always seen and the reaction to the virus may involve significant numbers of eosinophils. PCR has both false negatives and false positives and is best done on tissue cores rather than surface samples. Immunohistochemistry can be used to detect the presence of the virus in biopsy samples. This disease will get worse if corticosteroids are administered and will respond well to high doses of **fanciclovir**. Unfortunately in some cases, where tissue samples have not been diagnostic, we are left with no alternative but therapeutic trial. Off label doses range from 62.5-125mg 1-2x day

Mosquito bite allergy typically involves the nose and ears. The characteristic lesions consist of papules with a small black necrotic centre. These may coalesce to form areas of plaque or ulceration. The condition responds well to corticosteroids and resolution of the problem by confinement of the cat away from mosquitoes confirms the diagnosis.

Malassezia dermatitis is recognised in particularly Sphinx and Rex cats and in the Abyssinian. A greasy dark exudate on the skin and a brown coating on the nails is regarded as characteristic. Sticky tape cytology or examination of scrapings from the nails yields significant numbers of characteristic yeast bodies. It is not clear to what extent cases of *Malassezia* dermatitis in these particular breeds resents a genetic predisposition and/or a secondary overgrowth in reaction to allergy. *Malassezia* dermatitis responds to itraconazole, 5 to 7 mg per kilogram given daily for a week

on/week off basis for 6 weeks (three cycles). Topical treatment and control of the underlying allergic disease will further enhance clinical recovery.

Eosinophilic granuloma is just another reaction pattern in the cat, most commonly to allergy. Eosinophilic granuloma needs to be differentiated from tumours, infectious granulomas and Herpes virus infection and a biopsy is often required. Like other eosinophilic diseases of cats, eosinophilic granuloma will respond to immunosuppressive therapy and identification and elimination of the primary cause. An exception sometimes is the ulcerated lesions opposite the canine teeth on the upper lips. Some of these cases will respond better to antibiotics to corticosteroids. Linear granuloma is a variation of feline eosinophilic granuloma, which as the name suggests, has raised striped-like appearance.

Feline acne is not an allergic disease. Feline acne is a keratinization defect of hair follicles under the chin. This leads to black keratin plugging (comedones) and secondary infection. Pruritus is usually related to the secondary infection.

Clinical approach – a 3 step process

STEP 1 - eliminate ectoparasites, bacterial infections and dermatophytes

- Obtain a full clinical history. No shortcuts.
- Full dermatological examination including skin scrapings, impression smear cytology and Wood's light examination.
- Submit a toothbrush sample over at the least a one minute and submit the whole brush for fungal culture. If the suspicion of ringworm is high, it is rational to begin treatment in anticipation of the fungal culture results.
- If there is clinical or cytological evidence of pyoderma, treat for at least three weeks with oral doses of cephalexin (25 mg per kilogram twice a day), amoxicillin clavulanate (12 to 15 mg per kilogram twice a day) or 1 to 2 courses of cefovecin (Convenia ®) every two weeks.
- If there is furious pruritus, particularly of the head and neck, this needs to be stopped. Elizabethan collars, bandaging and, if needed, 7 to 14 days of prednisolone at 2 mg per kilogram daily. In cats that severely mutilate the neck area, the severe pruritus is compounded by deep infection which needs to be treated.
- Selamectin (Revolution ®) every 2-3 weeks is effective against surface and burrowing mites but is not effective against Demodex species.
- A full flea elimination trial is absolutely indispensable. Fleas need to be killed fast so they inject the minimum amount of saliva into the skin. All spot on preparations take too long to kill the flea and hence are not suitable for diagnostic trials.
- The author almost exclusively uses nitenpyram (Capstar ®) DAILY for at least six weeks. Compliance is assisted by using the large dog tablets divided into approximate quarters. In cases where cats are absolutely impossible to pill, Fipronil **spray** (Frontline ®) can be used every 7 to 10 days to minimise flea feeding.
- In cases where cats are using their claws to mutilate themselves, the use of corticosteroids is unavoidable however they need to be stopped at least two

weeks before stopping the daily Capstar and fortnightly Revolution so the results of the parasite elimination programme can be assessed.

STEP 2 - diet elimination and ensuring that none of the less common causes of pruritus are present.


If there has been a failure to respond to parasite pathogen elimination, we are left with a diagnosis of diet related pruritus, feline atopic dermatitis or one of the rarer diseases listed previously. If one of the rarer conditions is suspected, skin biopsies indicated. If, based on history and previous response to treatment, allergic skin disease is highly likely, we need to proceed to a diet elimination trial.

The gold standard for this is a minimum of eight weeks on a diet of a normal protein. Kangaroo or rabbit meat of human consumption standard is suitable. Hydrolysed low allergen diets are regarded by most dermatologists as the next best if the owner is unprepared or unable to feed a normal protein diet. Some cats just will not eat the elimination diet no matter what or will steal food/hunt. In these cases, it is just not possible to establish a diagnosis of food related dermatitis and we must proceed with the management of the cat as if it were atopic.

During the food trial, the use of corticosteroids is not contraindicated provided they are withdrawn at least two weeks before the diet rechallenge phase. A diet trial without rechallenge is an incomplete diet trial. Food allergic animals will relapse within 10 days of diet rechallenge (most commonly within 1 to 2 days)

It is quite acceptable, particularly in cases where parasites or parasite allergy is less likely, to begin the food elimination trial concurrently with the parasite elimination trial. It is imperative not to cease a test diet at the same time as ceasing to parasite elimination medication. The author's method is to continue the daily Capstar until two weeks after the diet rechallenge has been done. In this way it is possible to differentiate any response and establish an accurate diagnosis.

TIME LINES:



STEP 3 - Management of atopic dermatitis in cats

Atopic dermatitis is a clinical diagnosis, made after exclusion of the other possibilities. In all likelihood, atopic dermatitis will never be cured and will need lifelong management. The owner must be made aware of this. A corticosteroid only approach is highly likely to lead to serious side-effects and failure.

Corticosteroids in cats.

It is a common myth that cats are resistant to the side-effects of corticosteroids. It is true that cats require higher doses of corticosteroids to reduce pruritus or to treat immune mediated disease (roughly twice the doses used in dogs). The initial dose of prednisolone often needed to suppress pruritus is of the order of 2mg/kg once daily, that is to say half of 20 mg prednisolone tablet daily for an average sized cat .

Cats however, are not resistant to the side-effects of corticosteroids. Corticosteroid induced diabetes (type II) and heart failure due to plasma volume expansion well-recognised side-effects in the cat.

Typically, corticosteroid doses are reduced by 25% every 10 days until an absolute minimum dose is found that is needed to maintain the cat. The, however, rarely relies on systemic corticosteroids long term in the cat; preferring to maintain atopic cats cyclosporine and immunotherapy and occasional 3 -5 day pulses for flare-ups.

Depot corticosteroids should be used only as a last resort in cats that absolutely refuse oral medication (including oral prednisolone suspension). If a cat were to require no more than 2-3 depot methyprednisolone acetate injections over a 12 month period, this could be considered as reasonable management. However, with each injection, rises in blood glucose and plasma volume analogous to uncontrolled human Type II diabetes mellitus have been demonstrated.

The more potent topical corticosteroids, particularly those containing mometasone or betamethasone are effective in local lesions and reduce the dependence on systemic corticosteroids. Cat's licking will remove medication and result in increased systemic levels. Prolonged use of high potency topical corticosteroids will result in severe skin atrophy.

The use of antihistamines combined with a omega-3/6 essential fatty acids in cats may further reduce the doses and dependence on corticosteroids. Antihistamines and fatty acid supplements often are not effective alone in controlling the signs of atopic dermatitis. If they reduce the amount of immunosuppressive drugs needed, and they are worthwhile. Clinicians, however, need to consider carefully the benefits of antihistamines versus compliance if another medication is brought into the regime. The only antihistamine registered for feline use in Australia is chlorpheniramine. There are limited reports of the successful use of cetirizine at 1mg/kg daily in cats.

Megesterol acetate has been used in the past to treat pruritus in cats and provoked many cases of diabetes. The pseudo-disease described prior to 1980 as "feline endocrine alopecia" is in fact over-grooming due to allergy. If hair is examined under a microscope the distal ends are barbered to a square cut-off shape by the tongue rather than rounded end typical of endocrine disease. In the last 30 years, the author has not used megesterol acetate in a cat and would only do so if the only alternative were to be euthanasia.

Cyclosporine in cats

In the last 5 to 7 years, cyclosporine has become a widely used and effective off-label medication for the management of atopic dermatitis in cats. Most cats with

manifestations of feline atopic disease can eventually be maintained long-term with 25 mg of cyclosporine every 2 to 4 days.

Cyclosporine has:

- Much lower rate of serious side effects than corticosteroids (diabetes, heart failure). Post transplantation diabetes is recognised in humans but it's incidence in domestic pets is unclear.
- Main reported side effects are gastro-intestinal disturbances and weight loss. Most cases not severe enough to stop usage.
- Predisposition, through immunosuppression, to opportunistic infections.
- A much slower onset of actions. Owners need to be aware that will take at least three weeks for any benefit whatsoever to become apparent. Corticosteroids can be used during this lag phase to prevent serious self-mutilation.

Candidate cats for cyclosporine treatment

- FIV/FeLV negative
- No evidence of systemic disease
- Owners consent to off label use
- Rule out of other pruritic diseases: or
 - ✓ Flea allergy
 - ✓ Mites
 - ✓ Pyoderma & Malassezia
 - ✓ Adverse food reactions
 - ✓ Dermatophytes
 - ✓ Pemphigus
 - ✓ Psychogenic
 - ✓ Neoplasia

Cyclosporine and feline toxoplasmosis

- Uncommon complication, cases reported in the literature
- Both new infections and re-activation of latent infections are possible, New infections are regarded as important, placing sero-negative cats are at risk.
- To prevent new infections, client should be advised to cook all meat and to prevent hunting of rodents etc.
- No evidence of re-shedding of oocysts.
- Cats that hyper-absorb cyclosporine at higher risk. Normally, only about 25% of orally administered cyclosporine is absorbed by the cat.

Author's protocol

- Atopic dermatitis is FIRST confirmed by appropriate elimination trials.
- Informed consent is obtained from the owner.
- The cat is determined to be FIV negative and have no evidence of systemic disease.
- Cyclosporine is begun at a dose rate of 25 mg daily, one hour before food. After 4 weeks, a 24-hour post-pill trough cyclosporine blood level test (EDTA sample) should return levels of 200 to 500 ng per ml. Cats with levels at below 100 ng per ml may require increased doses. Cats with levels into the high hundreds or thousands are considered to be hyper absorbers and are at increased risk of toxoplasmosis. Hyper absorbing cats should have the dose rates rapidly reduced and further trough levels evaluated.
- Daily cyclosporine should be continued for 30 days or until significant clinical improvement is noted. In some cases, the full benefit of cyclosporine may not

be apparent for up to 10 weeks. If there is no benefit after 10 weeks of administration than the drug should be abandoned or the diagnosis of feline atopic dermatitis reassessed.

- Once clinical response has begun the dose can be reduced to every second day and then, if effective, to every three days and further with an interval of four weeks between reductions.

Immunotherapy in atopic cats

Immunotherapy in dogs has been shown to produce significant benefits in about 70% of cases. In cats, there is a lack of formal large-scale studies. However, most dermatologists agree that cats benefit from immunotherapy at least as well, if not better, than dogs. House dust mites are the most common allergen identified but significant numbers of cats will react to one or more plant pollen.

The problem lies in the testing. Serum IgE tests are available however studies have shown that both normal and atopic cats of and have similar levels of IgE to common allergens. Intradermal testing in cats is limited by the weak and transient nature of some of the skin reactions, resulting in a significant number of false negative results. To assist in interpretation, some dermatologists interpret the test both with and without an injection of intravenous fluoroscene and reading the size of the reactions with a UV light.

The author's opinion is that intradermal testing is still worthwhile because those cats that react positively will often show very good responses to immunotherapy.

References and further reading

Ahman S, Perrins N and Bond R (2007) Treatment of *Malassezia pachydermatis*-associated seborrhoeic dermatitis in Devon Rex cats with itraconazole--a pilot study. *Veterinary Dermatology* 18:171-4.

Diesel, A. and DeBoer, D. J. (2011), Serum allergen-specific immunoglobulin E in atopic and healthy cats: comparison of a rapid screening immunoassay and complete-panel analysis. *Veterinary Dermatology* 22: 39-45

Hill P (2006) Feline Allergic Skin Disease - What's New in Diagnosis and Management? in Hill's Symposium on Advances in Feline Medicine.
<http://www.ivis.org/proceedings/hills/felinemed/hill1.pdf>

Lappin M.R. (2008) Infectious disease risk in cats treated with cyclosporine WVDF Forum 2008 Hong Kong 360-365

Noli C et al (2004) : Papular eosinophilic/mastocytic dermatitis (feline urticaria pigmentosa) in Devon Rex cats: A distinct disease entity or a histopathological reaction pattern? : *Vet. Dermatol.* 15: 253-257

Noli C and Scarpella F: (2002) *Dermatologia del Cane e del Gatto*. Poletto, Milan.

Papich, M. G., E. K. Schooley, et al. (2008). "Pharmacokinetics of cetirizine in healthy cats." *Am J Vet Res* 69(5): 670-4.

Ployngam T et al , (2006) Hemodynamic effects of methylprednisolone acetate in cats. *Am. J. Vet. Res* 67:583-7

Prost C. Diagnosis of feline allergic disease, a study of 90 cats. *Advances in Veterinary Dermatology*, vol 3, C. von Tscharner et al eds, Butterworth Heinemann, Oxford. 1998; 516-517

Prost C. (2009) Feline Atopic Dermatitis. Signs and Diagnosis.
http://www.fecava.org/files/EJCAP%2019-3%20p%20223_229_Prost.pdf

Rust MK et al (2003) Efficacy and longevity of nitenpyram against adult cat fleas (Siphonaptera: Pulicidae). *J. Med Entom.* 40:678-81.

Vercelli, A., Raviri, G. and Cornegliani, L. (2006), The use of oral cyclosporin to treat feline dermatoses: a retrospective analysis of 23 cases. *Veterinary Dermatology*, 17: 201–206

Wisselink M and Willemse T (2008) The efficacy of cyclosporine A in cats with presumed atopic dermatitis: a double blind, randomised prednisolone-controlled study. *Vet Jnl* 180: 55-59

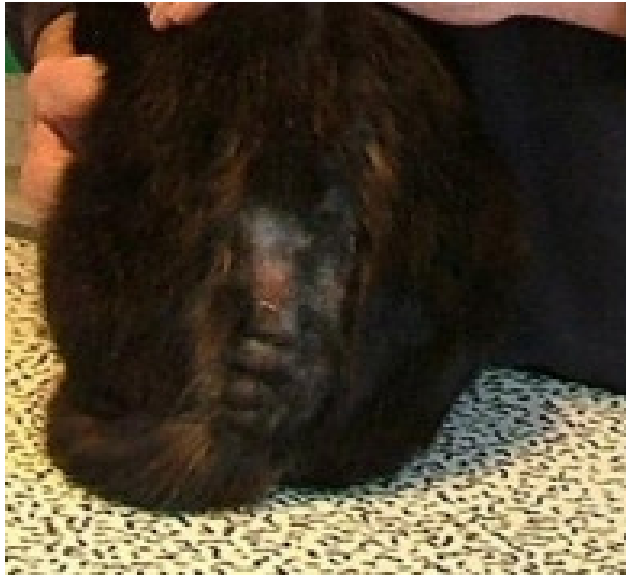

Figure 1 Lesions suggestive of flea allergy dermatitis. A treatment response trial would confirm the diagnosis

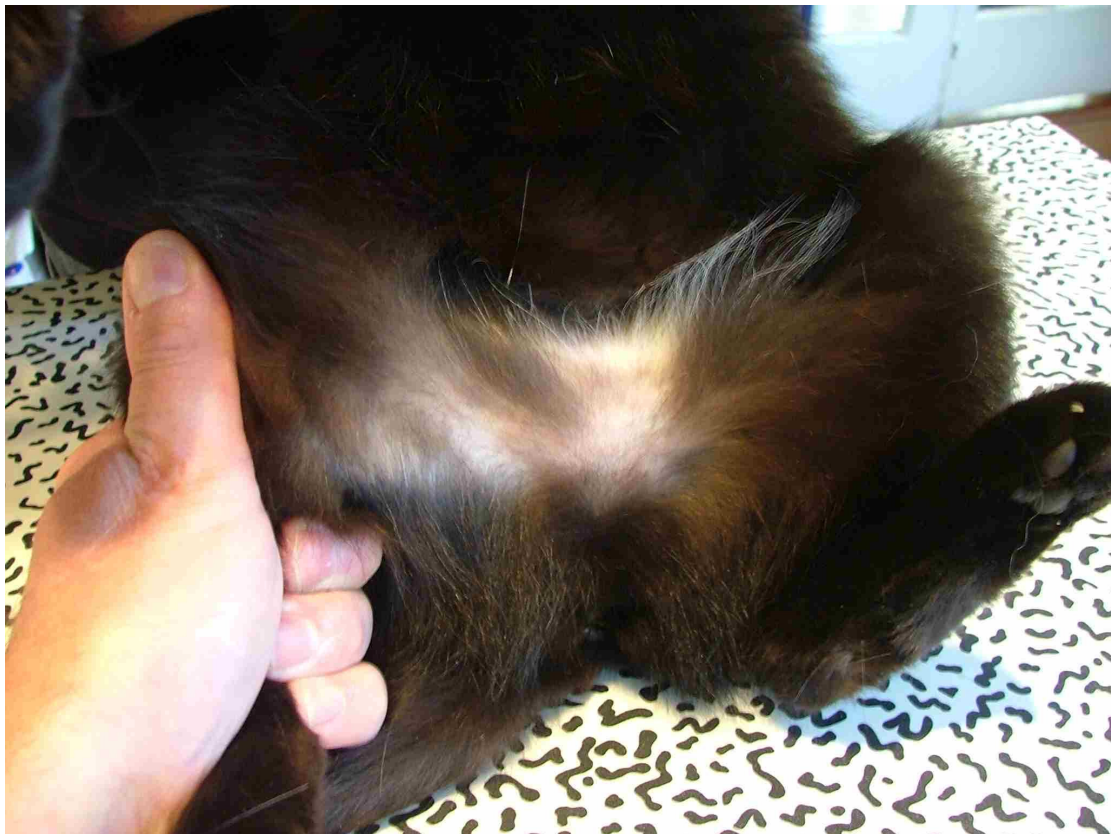


Figure 2 Alopecia from over grooming . Allergic skin disease is far more likely than psychological dermatitis.

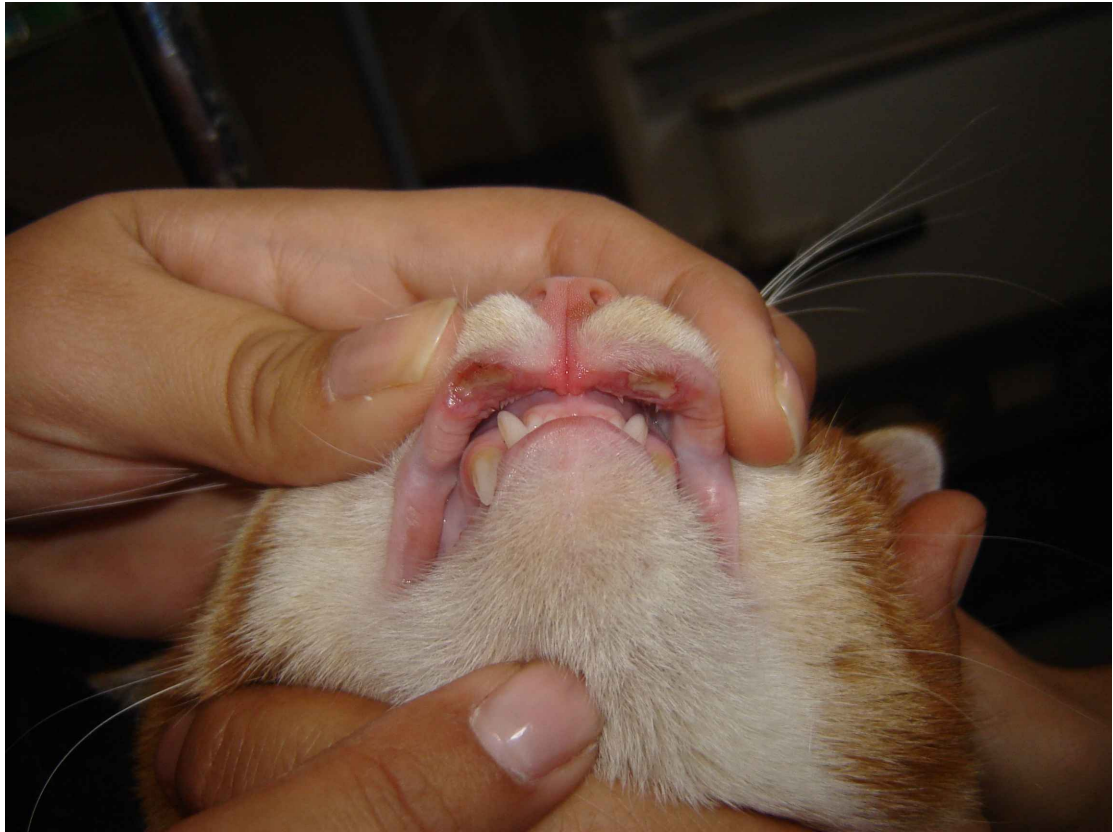

Figure 3 Rodent ulcer. Some cases will respond better to antibiotics than corticosteroids. (Dr V Balazs)

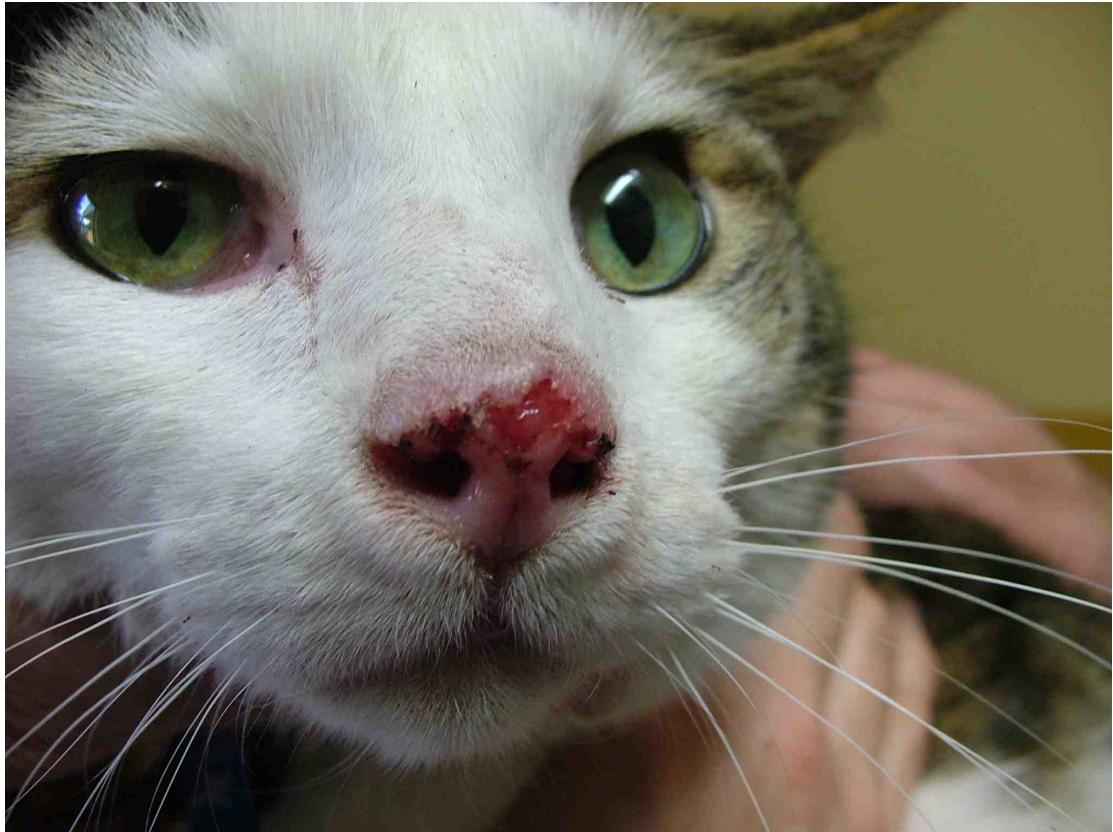

Figure 4. A biopsy, possible PCR and immunohistochemistry would be required to diagnose space this ulcerative lesion. Differentials include squamous cell carcinoma, feline herpes dermatitis, atypical infections and eosinophilic granuloma. The final diagnosis was feline herpes.

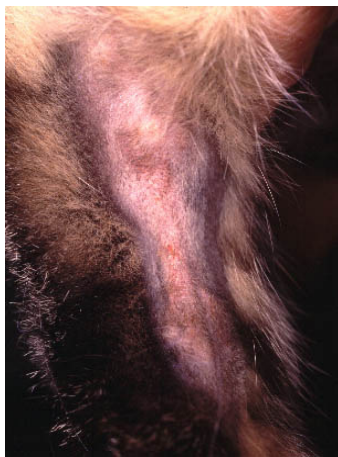

Figure 5 Linear granuloma. A variant of eosinophilic granuloma.

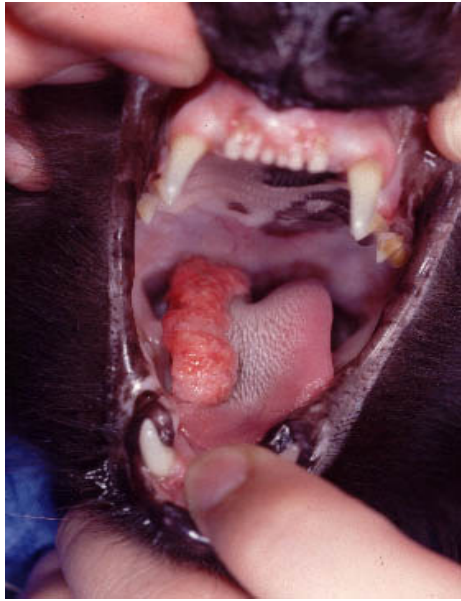

Figure 6. Oral eosinophilic granuloma may occur on the tongue, palette or at the fauces. Dr Candace Sousa

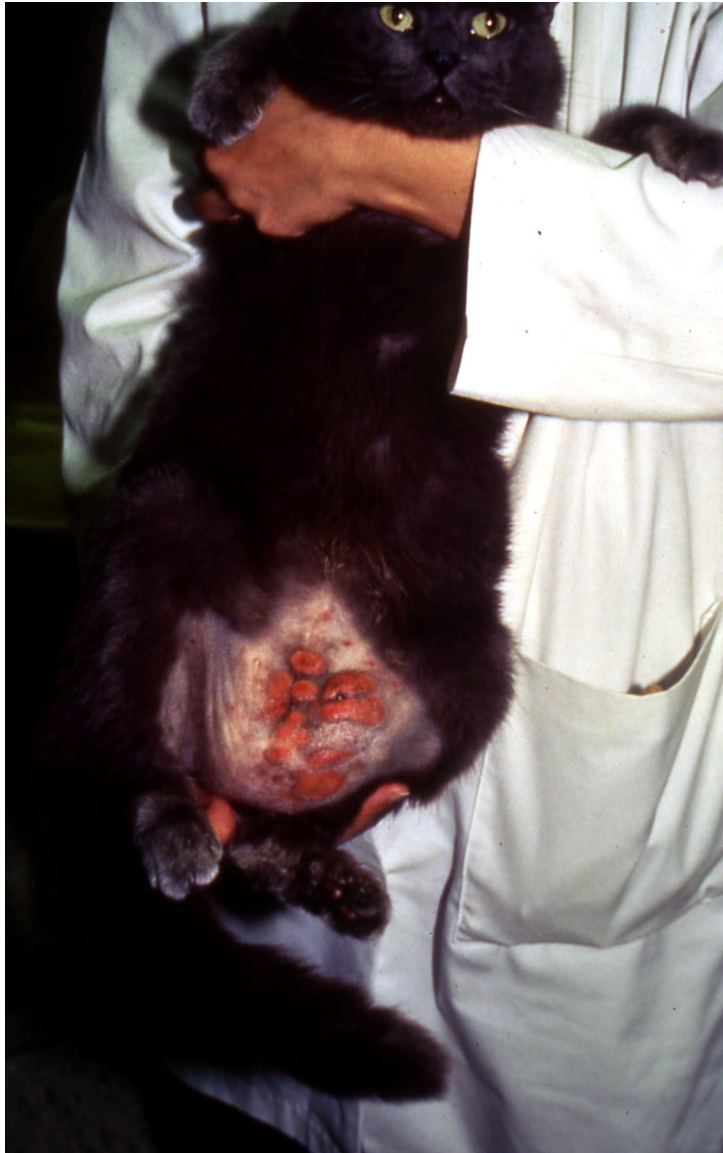

Figure 7. Eosinophilic plaque, most commonly reaction pattern to allergy. Dr. Michelle Rosebaum

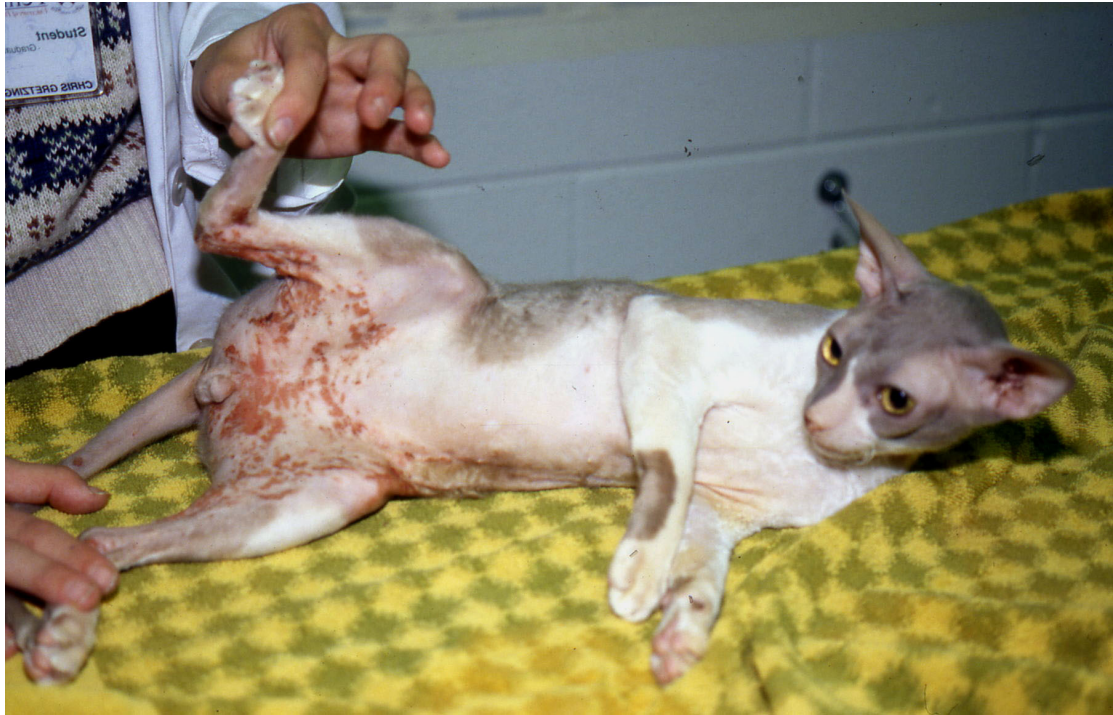

Figure 8. Urticaria pigmentosa occurs in Sphinx or Rex cats as a reaction pattern to allergy. The clinical appearance is that of erythema nodules and plaque. Dr M Rosebaum

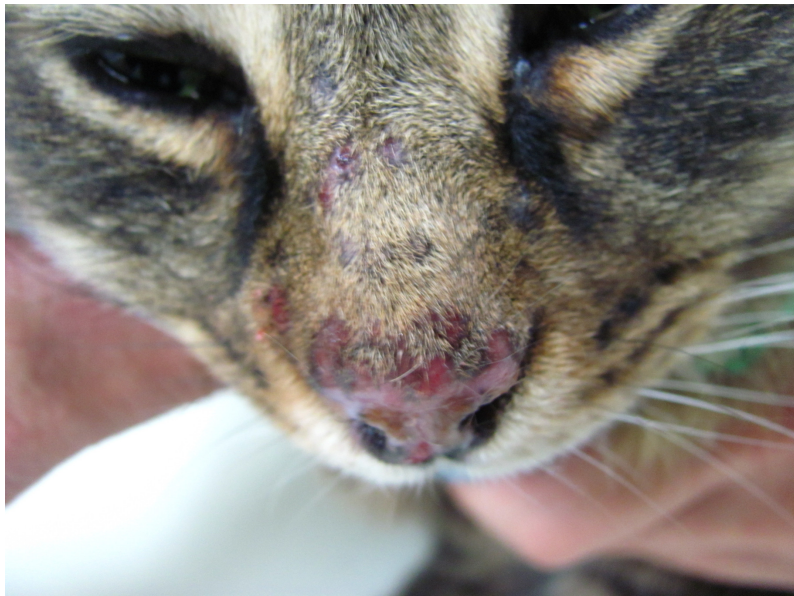

Figure 9. Clinical appearance of focal lesions that suggest mosquito hypersensitivity.

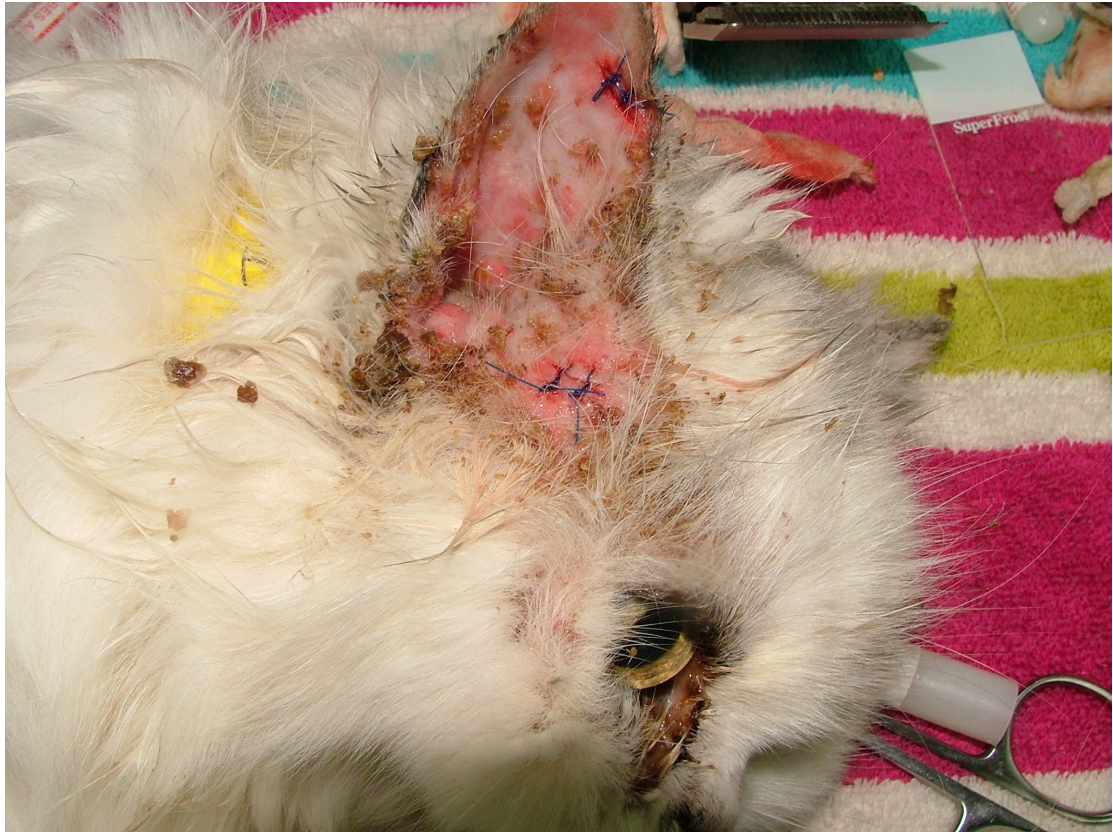

Figure 10. Yellow crusts and pustules that suggest pemphigus foliaceus. Cytology and a biopsy confirm the diagnosis.