

CHAPTER 16

METHODS OF INTERNAL FIXATION

DAVID M. NUNAMAKER

[◀ Prev](#) [Next ▶](#) [Home](#) [Contents](#) [Glossary](#)

- [Intramedullary Fixation](#)
 - Steinmann Pinning
 - Multiple Steinmann Pins
 - Rush Pins
 - Kuntscher Nailing
- [Screws and Plates](#)
 - Basic Principles of Fracture Treatment
 - Indications
 - Technique of Screw Fixation
 - Technique of Insertion
 - Plate Fixation
- [Orthopaedic Wire Techniques](#)
 - Full Cerclage Wiring
 - Hemicerclage Wiring
 - Tension Band Wiring
- [External Skeletal Fixation](#)
 - History
 - Biomechanics
 - Applications of Kirschner-Ehmer Apparatus
 - Indications
 - Complications
 - Pin Removal

The discussion of methods and techniques of internal fixation presented in this chapter is not exhaustive but includes those most useful in the majority of cases. Other techniques are described in chapters that deal with the treatment of specific fractures.

INTRAMEDULLARY FIXATION

Intramedullary fixation, with all of its attendant problems, is the most readily used system of internal fixation in small animals (6,11,37). In many respects it is the least understood and least sophisticated method. The techniques are adapted from use in humans, and very little research or further development of intramedullary fixation has taken place in veterinary orthopaedics. (19) In contrast to human orthopaedics where the number of appliances is limited only by one's imagination, the devices used in veterinary medicine include only the Steinmann pin, Kirschner wire, Rush pin, and Kuntscher nail, and of these, the Rush pin and Kuntscher nail are not used extensively.

STEINMANN PINNING

INDICATIONS

Intramedullary pinning with a single Steinmann pin may be indicated in fractures throughout the length of a long bone. It is best for transverse and short oblique fractures of the middle third of long bones. It can be applied in conjunction with cerclage and hemicerclage wiring, which will extend its indications considerably. Single or multiple Steinmann pins together with cerclage and hemicerclage wiring may be adapted for all types of fracture fixation.

BIOMECHANICS

The Steinmann pin, while the most commonly used intramedullary device in veterinary medicine, is the least sophisticated. Because it is placed in the medullary cavity, it resists bending in all directions. Its strength is related to its diameter, and its ability to restrict motion of the fracture fragment is related to its contact with the surrounding bony cortex. A small intramedullary pin in a large medullary cavity has been shown to be a successful method of producing nonunions (Fig. 16-1, A). Complications of intramedullary pinning with Steinmann pins can often be traced to mechanical factors such as pin migration, bending, or catastrophic failure. Delayed union and nonunion after intramedullary pinning may also be a result of mechanical factors. Since the medullary cavities of most bones in the dog vary widely in diameter, the Steinmann pin is usually used in three-point fixation. It is anchored at the point of introduction, has contact with the fractured surfaces and/or the isthmus of the medullary canal, and is impacted into the distal cancellous bone (Fig. 16-1, B). A round intramedullary pin can do little to prevent torsional instability in fracture fixation. The Steinmann pin may allow torsional stability only when it leads to interdigitation of the fracture fragments. In general, when an intramedullary Steinmann pin is placed alone for reduction and stability of a fractured long bone, it should contact as much of the medullary cortex as possible in order to provide some torsional stability. If intramedullary fixation does not present adequate stability against rotation, either multiple pinning, cerclage wiring, hemicerclage wiring, or external fixation must be used in conjunction with the pinning. Intramedullary devices provide no longitudinal support; the fracture fixation is dependent upon the stability of the fracture fragments themselves. Therefore, when comminution or cracks exist, there is a definite possibility for further collapse and

telescoping of the fracture fragments over the Steinmann pin.

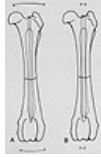

FIG. 16-1 Intramedullary pin size compared with medullary cavity diameter. (A) A small intramedullary pin allows significant movement and may result in pin loosening or nonunion. (B) A larger pin restricts movement and therefore aids healing. This drawing shows a properly fitting Steinmann pin that is anchored at three levels proximal femur, isthmus at fracture site, and distally in the soft cancellous bone of the metaphysis.

METHOD OF INSERTION

The Steinmann pin is inserted by using a Jacob's chuck. The pin should be introduced at the end of the bone, cross the fracture site, and become embedded in the distal metaphysis of the bone. Retrograde insertion of Steinmann pins is advocated by some and has the advantage of being technically easier to accomplish. However, complications of inadequate positioning and soft tissue (usually nerve) damage can be caused by improper retrograde pinning. The site for introducing a Steinmann pin in the dog's femur is in the subtrochanteric fossa. It may also be introduced distally in the femur through the intercondylar fossa (Fig. 16-2). In the humerus it is introduced through the proximal lateral aspect. The point of introduction is determined by the curvature of the humerus of the individual patient. In the humerus the Steinmann pin is started as far proximally as possible to still allow the pin to be positioned distally at the medial distal epicondyle. In the tibia, the Steinmann pin is introduced just medial and slightly behind the straight patellar ligament. In this position the pin enters the medullary cavity in front of the joint without invading it. In the ulna the Steinmann pin is inserted through the olecranon parallel to the medullary cavity of the ulna. Sometimes the intramedullary pin may be introduced retrograde in the ulna, but it is important that its direction be characterized so that the pin does not penetrate the elbow joint. I do not recommend intramedullary pinning of the radius owing to the inability to adequately stabilize the radius without interfering with a joint surface. Although introduction of the Steinmann pin into the radius in a retrograde fashion passing it out through the distal radiocarpal joint has been advocated in the past, there are better methods to achieve fixation of this bone.



FIG. 16-2 Pin position is shown for insertion through the intercondylar fossa of the distal femur in the treatment of supracondylar fractures.

The seating of a Steinmann pin is a very important part of its placement. After the pin has been introduced, crossed the fracture site, and reduced the fracture, it should be seated firmly in the distal fragment. The distance traveled by the pin is sometimes difficult to measure and should be planned before introduction into the distal fragment. This can be done easily by adjusting the chuck on the pin so that an adequate amount of pin will appear between the chuck and the surface of the skin; this distance is equivalent to the length of the pin that needs to be introduced into the distal fragment. Using this technique, it is relatively easy to establish a firm seating for the Steinmann pin without penetrating the joint surface below the fracture. As seating of the pin is achieved, the rotation that is necessary to insert the pin should be lessened to the point where only longitudinal pressure is applied to push the pin so that it may interdigitate with the cancellous bone. Steinmann pins are available with threaded tips. These threaded tips have no advantage and, in fact, cause stress concentration to occur at the junction of the shaft and thread, sometimes leading to breakage of the device. The trocar point is most often used for drilling and usually allows adequate seating of the pin in the distal aspect of the bone. Spade tips can be used when very soft bone is found and the Steinmann pin can be seated with a mallet to prevent rotation of this pin in the bone. After the pin has been cut off below the level of the skin, final seating with a mallet and countersink may improve the purchase of the pin in the cancellous bone of the metaphysis.

FOLLOW-UP TREATMENT

Fracture union is usually complete within 8 to 12 weeks following intramedullary pinning. In younger animals, this time may be reduced, and it is necessary to follow the dog very closely, especially if he is a giant breed, so that the pin may be removed before the bone "swallows" it up by growth. Intramedullary pins of the Steinmann type are generally removed after radiographs show evidence of periosteal bridging and usually after some degree of bone remodeling is noted in the callus itself. In other words, the callus should be resorbing and not proliferating at the time that the intramedullary pin is removed. Since the round intramedullary pin does not hold the fracture completely stable, considerable periosteal callus is sometimes noted. This callus is probably related to motion and will form a strong bridge across the fracture fragments, usually producing a desirable end result. The removal of the Steinmann pin is accomplished with a pair of pliers, pin puller, or grasping forceps by means of a stab incision through the skin. Early postoperative immobilization of the animal is necessary to prevent collapse or rotation of the fracture fragments following Steinmann pinning. It is important that the amount of rotational stability be accurately determined at the time of surgery, since further immobilization through the use of cerclage and hemicerclage wiring or external splinting or casting techniques may be helpful in limiting this rotation. Although every attempt is made to immobilize the animal, active movement of the joints and muscles of the affected extremity is encouraged.

CONTRAINDICATIONS AND COMPLICATIONS

Single Steinmann pins are usually contraindicated in severely comminuted fractures except when cerclage or hemicerclage wiring is added. Intramedullary pins are not good devices to use in the presence of sepsis. Insertion of a Steinmann pin into the marrow cavity of a septic fracture may cause the extension of infection throughout the medullary cavity and make the treatment of this infection very difficult. Steinmann pinning should be attempted only when the fracture can be made stable. Inadequate technique of Steinmann pin placement with improper seating in the distal fragment or instability of the fracture will lead to the complication of pin migration, the most common problem associated with intramedullary pinning. It is seen in animals where there is instability at the fracture site, allowing the fracture to collapse over the pin, or where there is sufficient motion to cause loosening of the pin at its distal aspect. If the pin loosens, the fracture will usually distract or collapse and

angulate. The pin may penetrate the skin through the site of initial insertion and create a tract for infection. The Steinmann pin should never be allowed to protrude through the skin when it is used for an intramedullary function. If this occurs, the pin should be removed and replaced immediately with a larger pin or some other form of fixation that will adequately stabilize the fracture. Simply reinserting the same pin after it has penetrated through the skin is not adequate treatment; this may serve only to be the focus for an infectious process, and the pin will usually begin backing out again several days later. If pin migration is a problem, it is evidence of instability at the fracture site and should be corrected immediately. Instability of the fracture, especially of the femur, will allow the formation of rotational deformities, usually an external rotation of the proximal fragment as a result of the pull of the iliopsoas muscle. This complication is very common and can be seen on the lateral radiograph (Fig. 16-3), which shows a femoral head that faces cranially. It will produce an abnormality in gait and should be prevented.

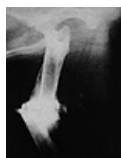

FIG. 16-3 Lateral radiograph of a canine femur. This animal presented with a rotational and angular nonunion caused by rotation around an intramedullary pin and angulation due to premature pin migration.

Steinmann pins are the most commonly used intramedullary devices in veterinary medicine. It is often used in combination with hemicerclage or full cerclage wiring to effect greater stabilization. Although at first glance it seems to be an easy technique to learn, it has a significant complication rate. Like any other technique, it requires sufficient planning and good technique to accomplish adequate results.

MULTIPLE STEINMANN PINS

INDICATIONS

Multiple Steinmann pinning is an outgrowth of Kuntscher nailing. It is an easier technique to learn than the latter and is useful in transverse and short oblique fractures in the middle half of the long bone. The technique is especially useful when trying to optimize torsional stability of the fracture site with round pins in large medullary cavities. The concept of multiple pinning is to fill the medullary cavity with an implant so that strong frictional forces between the pins and the inner cortical surface of the medullary cavity will prevent rotation. Multiple Steinmann pinning can be used in extensively comminuted fractures along with cerclage wiring.

BIOMECHANICS

The mechanics of multiple intramedullary fixation are similar to those of single intramedullary fixation except that the pins are packed into the marrow cavity in such a way that they are tightly adherent to one another and to the inner diameter of the cortical bone. This allows these round intramedullary devices to provide torsional stability to the fracture.

METHOD OF INSERTION

Introduction of multiple Steinmann pins into the medullary cavity of a bone may be accomplished in many ways. Although the pins can be inserted one by one, I prefer insertion of a small bundle of pins simultaneously. The technique for multiple intramedullary pinning of a bone will be described for the femur but is the same for any bone. An intramedullary reamer is introduced into the subtrochanteric fossa of the femur, which is reamed so that the hole created is approximately equal to the diameter of the medullary cavity (Fig. 16-4, A).

A group of four or five Steinmann pins of the same diameter, usually small, are bundled together and introduced into the proximal end of the femur. These pins are advanced easily down into the marrow cavity and the fracture is reduced and held with a bone clamp or a plate and two bone clamps, as will be described in the section on Kuntscher nailing. The intramedullary pins are then tapped gently down the marrow cavity into the distal fragment and seated with a mallet (Fig. 16-4, B). Seating is not done to its normal extent at this time. Additional Steinmann pins of the same diameter are taken from the surgical pack and introduced into the middle of this bundle of pins already in place (Fig. 16-4, C). As another Steinmann pin is driven into the group of pins, it will tend to spread the pins apart, allowing them to impinge on the inner cortical surface of the medullary cavity. In this way introduction of individual pins into the medullary cavity of the fracture site can be done with great care to avoid splitting the cortex. The fracture site is constantly observed and manipulated for evidence of rotation. When the fracture site is stable against rotation, there is no need to place additional pins. The pins are cut off individually with a pin cutter, and a small, round, stainless steel rod that serves as a pin set or countersink is used with a mallet to further impact the pins into the distal metaphysis and seat them below the greater trochanter (Fig. 16-4, D and E). The advantage of placement of several pins at once into the marrow cavity is that by bundling them in this fashion it is easier to keep them within the marrow cavity. Additional pins are placed, keeping them parallel with one another. Any distraction of the pins from one another during introduction is a sign that they are not parallel within the medullary cavity. This may indicate that the pins have been driven out through the fracture site or that some other complication of introduction has occurred and should be rectified. An alternative technique is to place single Steinmann pins one at a time with a Jacob's chuck, but this is often difficult because the chuck impinges on the previously placed pins, and seating of the pins becomes a problem.

FOLLOW-UP TREATMENT

Animals are usually walking on their legs between 3 and 7 days after treatment and are kept confined for the duration of fracture healing until there is radiographic evidence of bone union. Radiographs are usually taken at 6 weeks and then every other week or as needed. The intramedullary devices are removed following remodeling of bridging callus, which is usually several weeks after bony union has occurred. It is unusual to remove these intramedullary pins before 10 to 12 weeks postoperatively except in very young, rapidly growing dogs.

CONTRAINDICATIONS

Multiple Steinmann pinning has few contraindications. Longitudinal fragments may represent a hazard when using multiple Steinmann pinning techniques, but these can usually be controlled with the use of cerclage wires. As with single Steinmann

pinning, pin loosening or migration is a complication but can be minimized by using many pins. In general, when fixation has been accomplished with multiple Steinmann pins, only one or two pins will start to migrate, thereby saving the integrity of the fracture. It is important that these fractures be restabilized quickly before further comminution or pin migration occurs. Clinical experience suggests that pin migration is less common when smaller pins (and hence more pins) are used. It is not uncommon for me to use six or eight large Kirschner wires in the femur of a cat when employing these multiple pinning techniques.

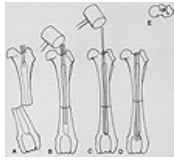


FIG. 16-4 Technique of intramedullary stacked pins. (A) Opening of the marrow cavity through the subtrochanteric fossa is accomplished using a reamer, drill bit, or large Steinmann pin. (B) The multiple pins are advanced easily with the use of a mallet. (C) Additional pins are added until marked resistance is encountered in adding more pins. (D) The finished product shows the advantage of many small flexible pins in securing a purchase in the distal fragment. Note the flaring of these pins as they impinge in the distal metaphysis. The pins should be at the level of or below the greater trochanter. This is accomplished with the mallet and pin set. (E) This drawing shows the relation of the pins to the medullary cavity in the transverse plane.

In many places multiple Steinmann pinning has replaced Kuntscher nailing owing to ease of insertion and the fact that individual pins can be added to the fracture if stability is insufficient; in contrast, a Kuntscher nail is either of the proper size or it is not. Introduction of too small a nail will result in motion at the fracture site, whereas introduction of too large a nail may cause comminution of the fracture. Both of these complications can be catastrophic. With multiple pinning the introduction of each small pin allows the fracture fixation to be checked so that sufficient fixation can be obtained without the disadvantages of Kuntscher nailing.

RUSH PINS

INDICATIONS

Rush pinning as described by Dr. Leslie Rush has very few limitations;⁽³⁵⁾ however, in veterinary medicine the main indications of Rush pins, when used in pairs, are for fractures of the distal humerus and distal femur.⁽³⁷⁾ Rush pins may also be used, again usually in pairs, to treat fractures of the central third of the diaphysis of both the humerus and femur in dogs. They can be inserted individually, but this technique has not been popularly embraced in veterinary surgery. Steinmann pins are usually preferred to single Rush pins.

BIOMECHANICS

The Rush pin is a specially tempered, round intramedullary device that is supposed to be quite springy. It has a hooked end that is used to drive and seat the pin into the bone and a tapered end that should bounce off the inner cortex of the bone as it is inserted so that it fits snugly against the inner wall of the medullary cavity. It is through the elastic bending of this intramedullary pin that the rigid fixation is accomplished. Since each pin usually gives two points of fixation, Rush pins are most commonly used in pairs. It is important that the pins themselves bend elastically during their insertion, rather than cause a change in the axis of the bone.

METHOD OF INSERTION

Insertion of Rush pins will be described for a supracondylar fracture of the femur. Following a lateral parapatellar incision, the supracondylar fracture is mobilized and reduced on the shaft of the distal end of the femur. Two Rush pins, approximately two thirds to three quarters the length of the diaphysis of the bone, are chosen. Both pins should be of the same diameter and length. It may be desirable to bend slightly the proximal end of the Rush pin in the same direction as the hook at the distal end to help introduce the pin into the medullary cavity so that its tip will bounce off the inner cortical surface. The distal fragment is reamed with an appropriate size Steinmann pin or Rush pin reamer before insertion of the pins. The introduction of the pin should be such that it is as distal and as far caudal as possible to permit being driven up to the medullary cavity. Thus, placement of the pins is lateral and medial to the trochlear ridges of the femur as close to the joint surface distally as is possible. The Rush pin reamer is started in the distal condyle with an angulation of about 10° to 30° from the long axis of the femur (Fig. 16-5, A). The smaller the animal, the smaller the degree of angulation. The reamer is used both medially and laterally across the fracture site, and the Rush pins are introduced and driven home simultaneously (Fig. 16-5, B and C). The Rush pins must be introduced into the medullary cavity concurrently so that deformity at the fracture site does not occur. They should bend elastically and pass up the medullary cavity without penetrating the cortex of the bone. The pins are tapped alternately until they are seated in the bony epiphysis. A special seating instrument is used to engage the hook of the Rush pin into the bone. At this point, reduction and stability of the fracture will be obtained and a routine closure is accomplished.

Occasionally Rush pins may be used for midshaft fractures of the humerus and femur. In this case one Rush pin may be driven from the medial side distally and the other Rush pin driven from the proximal fragment laterally. The crossing of the Rush pins at the fracture site is similar to when both pins are inserted from the same end of the bone but is usually easier to accomplish and may give better stabilization (Fig. 16-6). This method is especially useful in large medullary cavities that would otherwise be treated with a Kuntscher nail or multiple Steinmann pins.

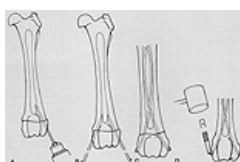

FIG 16-5 Technique of intramedullary Rush pinning. (A) A Steinmann pin in a Jacobs chuck is used as a reamer for the Rush pins. (B) The Rush pins are inserted as a pair to prevent unwanted axis changes in the reduction. (C) Final placement of the pins shows the elastic deformation occurring in the Rush pins. (D) Removal of the Rush pins involves using the impactor in the reverse direction.

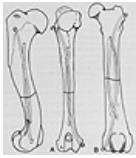

FIG. 16-6 Use of Rush pins in midshaft fractures of the humerus (A) and the femur (B)

FOLLOW-UP TREATMENT

The stable fixation that is achieved with the use of Rush pinning usually allows immediate postoperative weight bearing, which occurs within 3 to 5 days. Since the pins are well seated, they are often difficult to remove after fracture healing has occurred, usually within 8 to 12 weeks, and are, therefore, usually left in place. If removal is required, a small skin incision is made over the area of original insertion and the site of the pin is found with a curette or bone chisel. The extraction is then accomplished using the impactor in the reverse direction, gently tapping out the Rush pin from the medullary cavity ([Fig. 16-5, D](#)).

CONTRAINDICATIONS AND COMPLICATIONS

Since Rush pins are actively inserted into the marrow cavity by tapping with a mallet, it is of utmost importance that the cortex be relatively mature, dense, and without cracks. These pins are contraindicated in very young animals (under 4 to 6 months of age) in whom the marrow cavity is large and the cortex is soft and may be easily penetrated by the Rush pin instead of allowing the pin to glide over its inner surface.

Contraindications include any animal that has had a long episode of disuse atrophy in which the soft cortical bone may not be sufficient to support the Rush pin. In very young animals the distal epiphysis is very soft and may be damaged as the pin is driven through it during seating. Premature closure of the physal growth plate can also occur in young dogs subjected to Rush pinning. To prevent this, the literature suggests early removal of the pins if used in young animals.

Most of the complications of Rush pinning are related to improper technique and can be evidenced at the time of surgery. Use of Rush pins in dogs with soft cortices allows the Rush pin to protrude through the cortex in an improper fashion. The soft bony epiphysis of young animals allows the Rush pin to be driven through the epiphysis, thereby providing inadequate stability and damage to the growth plate. The Rush pin itself, because it is rigid, will cause rapid closure of the growth plate if left unattended. Removal of the pin after one month of fixation, as recommended in the literature, may not give adequate time for bony healing in some instances. ([46](#)) The act of removing a Rush pin from a very young dog may have a mutilating effect upon the bony epiphysis in which it was inserted. When Rush pins are seated, they may sometimes cause rotation or angulation of the fragments that are being compacted. This is often very difficult to correct and is one of the reasons that Rush pins have not achieved greater popularity in veterinary surgery. Properly handled, the Rush pin is a valuable tool that can be used for many types of fractures. Results are dependent on the skill of the surgeon, and its proper insertion is certainly more difficult to master than Steinmann pinning.

KUNTSCHER NAILING

Kuntscher nailing in veterinary surgery was introduced, pioneered, and enthusiastically advocated by the late Dr. Jacques Jenny. ([19](#)) His extensive experience in using V- and "cloverleaf" shaped Kuntscher nails has given us optimal indications for the use of Kuntscher nailing in small animals. Indications Kuntscher nailing is indicated for middle third, transverse, or short oblique fractures of the humerus, tibia, and femur when no longitudinal cracks or fissures of the bony cortex are present.

BIOMECHANICS

The Kuntscher nail is designed to stabilize the bony fragments by filling the marrow cavity and contacting as much of the cortical bony surface as possible. In humans this contact surface is increased by intramedullary reaming. In the dog, intramedullary reaming is contraindicated because the cortices are relatively thin and the diameter of the marrow cavity changes markedly throughout the length of the diaphysis. Therefore, in the dog the Kuntscher nail is usually used as a three-point fixation device. The initial point of fixation is the penetration of the nail through the proximal portion of the bone. The nail is then stabilized in the central portion of the fracture site, usually at the area of the isthmus of the marrow cavity, and distally is anchored in the cancellous portion of the bone of the distal diaphysis. The concept of the triangular or cloverleaf shape of the Kuntscher nail allows contact to be made along the marrow cavity in at least these three places. This is the one advantage of the Kuntscher nail over a firm-fitting round intramedullary pin of the Steinmann type. The Kuntscher nail allows point contact on the inner medullary surface of the cortex, which will help prevent rotation of the bone fragments. The nail itself is a relatively weak appliance when subjected to torsional forces. That it never breaks in canine application is due to the fact that large torsional forces are not usually present or that the nail does not fit tightly enough in the medullary cavity to prevent bony rotation.

METHOD OF INSERTION

The Kuntscher nail is best inserted from the proximal end of the bone distally. Retrograde insertion may lead to erroneous placement in the marrow cavity, particularly in the proximal femur, and result in catastrophic problems associated with avascular necrosis and fracture of the femoral neck, penetration and laceration of the sciatic nerve, and comminution of the formerly transverse or short oblique fracture. The technique of insertion of the Kuntscher nail will be described for a midshaft femoral fracture. A standard lateral approach is made to the main shaft of the femur with minimal exposure. However, the exposure must be adequate to surgically deride the ends of the fracture fragment, examine the fracture surfaces to ascertain that there are no longitudinal fissures or cracks that were not seen radiographically, and reduce the fractured fragments. The debridement of the marrow cavity is carried out prior to reduction to remove any small chips of bone that may be present. These small chips might impede introduction of the nail and cause further fragmentation of the bone. To perform adequate Kuntscher nailing without intramedullary reaming it is necessary to reduce the fracture ends of the bone anatomically as far as the intercortical surfaces are concerned. To penetrate into the marrow cavity a reamer or awl is inserted just medial and slightly behind the greater trochanter into the subtrochanteric fossa. The reamer is then pushed distally and penetrates into the middle of the proximal femoral medullary cavity. It is advanced until it reams approximately

the diameter of the Kuntscher nail that is to be used. The determination of size of the nail to be used is made by introducing the nail into the marrow cavity of the smaller diameter fragment at the fracture site. The nail should slide easily through the medullary canal but should not be so loose that it rattles. After penetrating the subtrochanteric fossa to the proper depth with the reamer, a small Steinmann pin, which is capable of being inserted through the cloverleaf or in the V of the Kuntscher nail is inserted into the proximal femur across the fracture line and is used in establishing reduction of the fracture. After reduction is accomplished, stabilization of the reduction may be achieved with bone clamps or with a small plate and two bone clamps to provide temporary reduction and stability at the fracture site during the insertion of the nail. The proper length of the nail may be obtained by removing the Steinmann pin after stabilization of the reduced fracture and cutting the nail to this length. The length of the Kuntscher nail should be such that when seated in the distal metaphysis, the head of the nail is located just distal to the greater trochanter in the subtrochanteric fossa. The Steinmann pin, which had been removed to measure the length of the Kuntscher nail, should be reinserted into the marrow cavity, and the proper size nail is driven over the pin using a mallet ([Fig. 16-7, A](#)).

Care must be taken when driving the nail to ensure that it is in alignment with the Steinmann pin and the medullary cavity of the bone. Careful observation at the fracture site is necessary to prevent distraction of the bone fragments, which may be a sequela to a nail that is too long or placed improperly. With each tap of the mallet the nail should progress satisfactorily; if tapping does not cause the nail to progress and the ringing of the mallet becomes more high-pitched, it is important to stop and ascertain the reason before continuing. Further impaction of a jammed nail may cause comminution at the fracture site and may prevent the Kuntscher nail from being an adequate form of internal fixation. A nail puller is a necessity when trying to remove a jammed Kuntscher nail.

Introduction of the nail is performed with the open section facing posteriorly. It is important in choosing a V-shaped Kuntscher nail to make certain that the tip of the nail is centered in the nail itself. Many nails are produced in such a way that the V tip is located at the base of the V, allowing the nail to be wedged into the cortex when driven and placing the nail eccentrically in the distal fragment, which again may cause problems. Nails of cloverleaf design usually contain no such point, hence this is of no concern. In some dogs with large anticurvature of the distal femur, slight prebending of the nail may be necessary to allow the nail to be seated in the distal metaphysis. It is important not to bend this nail to any great degree, since it still must progress through the relatively straight proximal portion of the diaphysis. After the Kuntscher nail has been driven across the fracture site, the Steinmann pin is removed and the nail is seated. The nail should seat itself distally into the metaphyseal cancellous bone at the distal fragment and should be below the greater trochanter proximally ([Fig. 16-7, B](#)). Following seating of the nail, the clamps that were used to maintain reduction of the fracture and hold the immobility during the nailing procedure can be removed; bone grafts can be accomplished at this time if necessary. Manipulation of the fracture should ensure its stability before the wound is closed.

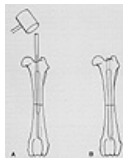

FIG. 16-7 Technique of intramedullary Kuntscher(K) nailing. (A) A K-nail introduced over a guide pin. (B) The nail is seated properly after removal of the guide pin.

FOLLOW-UP TREATMENT

Kuntscher nailing involves restriction of activity until there is radiographic evidence of fracture healing. Most dogs will be up and walking in 3 to 5 days postoperatively. It appears that fracture healing takes slightly longer with this method than with other forms of intramedullary fixation, probably as a result of the extreme rigidity with which the fracture is held. It is not unusual to see radiographic evidence of fracture healing between 12 and 16 weeks. The nail is removed only after there is radiographic evidence of bony union and usually after some cortical remodeling has occurred. Although the Kuntscher nail is difficult to drive in, its removal following healing is relatively easy and can be accomplished with the use of any grasping instrument, as well as with the nail puller. The nail itself usually becomes quite loose after healing has occurred and, in fact, may cause lameness, which ceases upon removal of the nail.

CONTRAINDICATIONS AND COMPLICATIONS

The Kuntscher nail should never be used when there are longitudinal, cortical cracks in either the proximal or distal fragments of the bone involved. Occasionally these cracks cannot be appreciated radiographically and are seen only on careful scrutiny at the time of open reduction of the fracture fragments. Although full cerclage wiring can be used in such instances, I do not recommend it. Untreated, these longitudinal cracks may expand as the nail is driven into the fragment and transform a simple transverse fracture into a comminuted one following impaction and seating of the nail. The Kuntscher nail has only limited value in comminuted fractures.

The instrumentation needed for the nails in small animals includes those instruments used in Steinmann pinning, as well as a reamer, mallet, and Kuntscher nail puller. This latter instrument is very important, since it may be the only tool that will extract a jammed nail at the time of reduction. Never use a Kuntscher nail without the availability of a nail puller!

Most of the complications of Kuntscher nailing are related to improper technique and occur at the time of insertion. These include the positioning of the nail through retrograde placement, which can result in avascular necrosis of the femoral head and neck; impingement of the nail in the hip joint; laceration or mutilation of the sciatic nerve; and wedging of the nail in the marrow cavity, causing comminution upon insertion. The usual complication of nail loosening and migration is prevented by using the proper size nail that is inserted and seated in a distal metaphyseal bone. Migration of the nail may be evidenced by a dog in extreme pain as the result of the impingement of the nail against the sciatic nerve as it protrudes through the subtrochanteric fossa. This represents an emergency situation in which the nail must be removed or seated properly. The use of round intramedullary pins may create the same problem. If the tip of the nail has protruded through the skin, the nail must be removed and another nail or some other form of fixation used. The reinsertion of a nail that has protruded through the skin is contraindicated because of potential contamination and subsequent infection of the marrow cavity.

OTHER BONES

The introduction site of the Kuntscher nail in the humerus is best determined from the lateral radiograph in which a straight line is drawn from the distal medial condyle up through the marrow cavity; its exit on the anterior surface of the humerus indicates the approximate place where the nail would be inserted. This can best be determined using the proper sized nail as an overlap on the radiograph prior to surgery. The nail is inserted in the tibia in the same manner as a Steinmann pin, just medial and slightly behind the tibial crest. The size nail used in the tibia is usually much smaller than would seem necessary, since the tibia has an S shape and the nail, which is straight, impinges on the convex surface of the medullary bone as it is driven distally. Kuntscher nailing is particularly useful in the cat, in which the medullary cavities in most long bones are long and parallel. This allows good positioning of the nail against the inner cortices and provides adequate stabilization of the fracture fragments. Closed intramedullary nailing of the femur, although commonly done when using reaming techniques and fluoroscopy in other species, is not widely performed in the canine. Kuntscher nailing, although very useful and extremely rigid, has been replaced in many instances by stacked intramedullary pinning, which technically is far easier to accomplish.

SCREWS AND PLATES

Although plate-and-screw techniques have been used sporadically in veterinary medicine for a long time, they have become a popular method only in the last decade. The Swiss AO (Arbeitsgemeinschaft für Osteosynthesefragen) or ASIF (Association for the Study of Internal Fixation) group caused a resurgence of interest in the human orthopaedic field after their organization was created in 1958⁽²⁷⁾. The four principles of this group (anatomical reduction, stable internal fixation, atraumatic technique of bone and soft tissue, early pain-free active mobilization following surgery) seemed to fit perfectly the needs of veterinary orthopaedics.⁽¹⁴⁾ The experiences with this technique in veterinary orthopaedics, which now span more than 15 years, have been an unqualified success, and the instrumentation has been widely copied.⁴² Today the proper use of plates and screws for fracture fixation in animals represents one of the most sophisticated and reliable forms of internal fixation available.^(8,14)

BASIC PRINCIPLES OF FRACTURE TREATMENT

The basic philosophy of the ASIF techniques as used in small animals is functional fracture treatment provided by stable internal fixation and early mobilization of the joints with partial weight bearing followed later by full weight bearing. This functional fracture treatment is achieved through accurate anatomical reduction and interfragmentary compression of bone fragments such that the injured bone itself transmits and shares the loads of weight bearing with the fixation. Exact anatomical reduction can be accomplished with screws alone or with screws and a plate. The close contact of the fragments, which is necessary for stability of the reduced fractures, can be achieved with interfragmentary compression. Complete reconstruction of the bone is absolutely necessary in order to transfer weight-bearing loads through the bone, thus not depending entirely on the implant for weight bearing.

INDICATIONS

Screws can be used by themselves for fractures of the femoral neck and for intercondylar fractures of the distal humerus and femur. In these situations one screw is often used together with a Kirschner wire to prevent rotation. Screws should never be used alone for diaphyseal fractures, since weight bearing will cause loosening and collapse of the fracture site. Screws are used together with plates for diaphyseal fractures and all comminuted fractures of long bones, including fractures into joints.

TECHNIQUE OF SCREW FIXATION

Screws are inserted into the bone through drill holes. The process of drilling is an important one, since the interface between the screw and the bone should be complete. The use of a hand drill or brace usually causes a large amount of drill bit wobble, which produces oval holes that will not allow maximal purchase by the screw, thereby weakening the internal fixation. Therefore it is recommended that a power drill be used whenever possible. Even with a power drill it is helpful to use drill guides to prevent wobble and the formation of oval holes. A good drill bit should drill approximately 1 mm of bone per second. Drilling at rates slower than this can produce thermal damage in bone. Cooling of a drill hole to prevent thermal necrosis is impractical, since over 500 ml of saline per minute must be used to adequately cool the drill site.⁽²⁶⁾ Saline irrigant is useful, however, as a lubricant to speed the cutting process, thus reducing friction and the generation of heat. The heat generated in a drill hole is usually removed with the swarf material from the drill bit. Periodic cleaning of the drill bit to remove the swarf material will, therefore, remove heat and allow a place for more material to accumulate, thereby speeding the drilling process. Pretapping drill holes before insertion of the screw permits a screw to be inserted with less torque. This lower torque at insertion will in turn allow the screw to generate more axial compression before friction causes the screw to feel tight. Pretapped drill holes guarantee easy removal and reinsertion of the screw in the same hole without the danger of cross threading the hole. A prethreaded screw hole also allows selection of a screw of the correct length so that an excessive amount of screw shaft is not exposed on the far side of the cortical bone before full thread engagement of the bone has occurred.

There are two basic types of screws the fully threaded cortical screw and the partially threaded cancellous screw. Both screws are available in a wide variety of sizes necessary for the varied problems that arise in small- animal orthopaedics. The efficacy of the various screws depends on the location where they are used and on the function that is expected of them. In general, canine bone is relatively hard and the use of a cancellous screw at any location is rarely necessary. Cortical screws are adequate for nearly all applications in the dog, except in some young, growing dogs and dogs with disuse osteoporosis, as well as those with metabolic bone disease. Cancellous screws should be used only when failure (stripping) of a cortical screw has occurred or in an animal in whom previous drill holes have indicated that failure of the cortical screw is likely to occur.

CORTICAL SCREWS

A cortical screw is a fully threaded screw that produces interfragmentary compression by means of a large gliding hole in

the ciscortex (near cortex) and a smaller threaded hole in the transcortex (far cortex). Cortical screws are available in sizes that range from 1.5 mm to 4.5 mm thread diameter. Testing of the various screw sizes has been done, and the results show that in general the softer the bone that is encountered the larger the screws that should be used.³⁰ In hard cortical bone the differences between the 2.7-mm and 3.5-mm cortical screws are negligible. In softer bone the larger 3.5-mm screw would be better than the smaller 2.7-mm one. To use a cortical screw as a lag screw it is necessary to use a large drill bit equivalent to the outside diameter of the screw thread to drill the gliding hole through the ciscortex while a smaller drill bit equivalent to the approximate core diameter of the screw is needed to drill the smaller threaded hole into the transcortex. In this way a fully threaded cortical screw can be used as a lag screw just as can a partially threaded cancellous screw.

After reduction of the fragments and temporary fixation with a bone-holding forceps, Kirschner wires, or other device, a large gliding hole is drilled through the ciscortex (Fig. 16-8, A). A drill insert is then placed into this hole and pushed through until it engages the opposite transcortex. This drill insert has the same outside diameter as the gliding hole that was drilled previously and an inner diameter that will accept the drill bit for the smaller threaded hole in the transcortex. The insert functions to center the pilot hole precisely in relation to the gliding hole. The hole in the transcortex is then drilled with the proper size drill bit (Fig. 16-8, B), and the hole is countersunk to provide a seat for the head of the cortical screw following removal of the drill bit and insert (Fig. 16-8, C). It is important to turn the countersink in a 360° circle in order to avoid a rough surface on which the screw head will be seated. The countersink is used sparingly, just enough so that the head of the screw will contact the hole throughout its circumference. This prevents stress concentrations at the screw hole and bending of the head of the screw during insertion. The hole is then measured with a measuring device to determine the proper length of screw to be used in the hole (Fig. 16-8, D). A cortical tap is inserted into the gliding hole and the threads are cut into the bone in the transcortex (Fig. 16-8, E). The taps should be advanced two half turns forward and then back one quarter turn in order to free the swath material from the threads. It is important that this tap move easily. If binding occurs, further advancement of the tap should cease and the tap should be removed from the hole and cleaned. Frequent cleaning of the tap is necessary to remove the swath material from the longitudinal grooves, thus allowing easy advancement of this instrument in the hole. After the threads have been cut satisfactorily, a screw of the proper length is inserted and tightened (Fig. 16-8, F). Saline or balanced electrolyte solution added as a lubricant during the drilling, tapping, and insertion of the screw into the hole will reduce friction and make the insertion of the screw easier. Occasionally, because of a long, narrow, posterior spike on the transcortex, it is necessary to drill that cortex first and then reduce the fracture. Here the hooked drill guide can be used, allowing the gliding hole to be placed after reduction of the fracture. The screw is then placed following the steps outlined above. This technique is usually necessary only if drilling of the pilot holes through the drill insert could result in inappropriate placement of the screw in the fracture line or missing of the opposite fracture fragment completely. The position of the screw relative to the fracture site is very important. In general, stability is achieved across fracture surfaces by normal forces, that is, forces that are perpendicular to the fracture plane. Shear forces (forces parallel to the fracture plane) may cause sliding and instability of the fracture. Therefore, to ensure stability through high frictional forces, screw placement should result in the creation of high normal forces and the prevention of shearing forces. In spiral fractures this is accomplished by following the spiral with the interfragmentary screws to maximize the normal forces in the transverse planes. The problem becomes more complicated when dealing with a longitudinal plane. Here, high normal forces are desired, but in addition to the loading of the bone by the screw (interfragmentary compression) there is also an axial load on the bone mediated through weight bearing. Therefore, it is important to balance the effect of screw interfragmentary compression with the expected load bearing so that the combination of the two forces will result in high normal forces across the fracture line.

Based on theoretic considerations and practical experience, very long oblique fractures are usually stabilized with screws that are inserted perpendicular to the long axis of the bone. In most other fractures the screws are inserted halfway between perpendicular to the long axis of the bone and perpendicular to the fracture site itself. Rarely is an interfragmentary screw placed perpendicular to the fracture plane without use of additional screws and/or a plate. In all cases, the resultant forces carried across the fracture surface should be normal ones.



FIG. 16-8 Technique for placing an interfragmentary cortical bone screw. (A) The large gliding hole is drilled using a drill guide. (B) The smaller- threaded hole is drilled using the insert to center the hole precisely. (C) The countersink is used to align the screw head to the hole in the shaft to prevent bending of the screw head. (D) The hole is measured using the depth gauge. (E) The hole is tapped. (F) The screw is placed, producing interfragmentary compression

CANCELLOUS SCREWS

A cancellous screw is a partially threaded screw that exerts its interfragmentary compression by having all its threads on one side of the fracture plane; these threads exert their force against the head of the screw, which rests on the other side of the fracture. In no instance should the threads of a cancellous screw be on both sides of the fracture fragments. If this were the case, interfragmentary compression would be absent and failure of the implant would be likely to occur at the junction of the shaft and threaded portion of the screw or at the fracture line following weight bearing. The cancellous screw, being a partially threaded screw, produces interfragmentary compression using a single-diameter drill bit and tap to allow the screw to obtain purchase only at its distal threaded end. In this way the proximal portion of the screw slides through the ciscortex, and seating of the head of the screw into the bone allows the interfragmentary compression to occur. The cancellous screw or special purpose screw is available in two diameters—4 mm and 6.5 mm, and the large 6.5-mm screw is available in two thread lengths—16 mm and 32 mm. As stated above, the cancellous screw is used only in soft cancellous bone in which a cortical screw would not hold.

Cancellous screws have two limitations for use in hard cancellous or cortical bone. If such a screw is placed in cortical bone, the cortical bone may grow around the shaft of the screw, thereby making it difficult or impossible to remove the screw following fracture healing. During removal, the screw will back out to a certain point and usually will break at the junction of the shaft and end thread. To remove this threaded portion, a trephine device must be used, which will result in a large defect

that then becomes a stress concentrator. Worse yet, the screw may crack the thin cortical bone of the dog, producing a new incomplete fracture upon removal. Another problem with any partially threaded screw is that there is a stress concentration normally occurring at the junction of the thread and the shaft. Although one cannot presume that the screw will break during insertion in normal canine bone, it is possible for the threaded portion to fracture from the shaft, especially if the junction occurs just at the fracture line. In this case the threaded portion of the screw is difficult to remove.

TECHNIQUE OF INSERTION

After reduction of the fracture fragments and temporary fixation with the bone-holding forceps, Kirschner wires, or other device, a hole of proper dimension is drilled through both cortices. The countersink is used to provide a seat for the head of the cancellous screw, and the hole is measured using a depth gauge. The cancellous tap of the proper size is used to cut the thread into the bone. Again, the tap should move easily and be backed off periodically to remove the swarf material from the cutting threads. The usual routine is two half turns forward then one quarter turn backward. The tap should never be advanced if met with great resistance, since it may break. Because the tap of the cancellous screw is not of the full dimension of the screw thread, there is additional cutting of the bone by the thread of the screw when the screw is inserted after tapping. When using the 6.5-mm cancellous tap, the depth readings are shown on the tap, thereby eliminating use of a separate depth gauge.

PLATE FIXATION

The selection of a plate for internal fixation of a long bone must be made carefully because of the wide variety of type of plates available. There are six major cross-sectional area size plates and two basic hole types. It is important to choose a plate of correct length, also. When using a plate with a round-hole design, the proper size plate must be chosen so that the tension device can be used at the end of the plate. When using the dynamic compression system, the tension device need not be applied; therefore, a plate approximately one or two hole lengths longer can be used. The technique for applying the plate will be described using a standard round-hole Muller ASIF plate with the 4.5-mm cortical size screw hole (Fig. 16-9). This plate is available in both the narrow and broad configuration and each type plate can be used as described below. The technique for the other size plates and screws is the same as will be described, but the instrumentation for these plates has been sized to the particular plate in question. Table 16-1 shows the correct size of instruments (tap and drill bit size) for each screw size to be used in each plate. It should be noted that two types of 3.5-mm cortical screws are available with different core diameters, thread pitch, and associated instruments for insertion. The larger-cored 3.5-mm screw has been used in our clinic since 1972 and represents a significant improvement for fixation in canine bone. If only one 3.5-mm screw were to be used, I would recommend this one.

After determining its proper size and length, the plate should be contoured to the bone very accurately. This is done using a bending press so that the plate is made to lie directly on the surface of the bone. The plate is then placed on the fracture site and centered over the fracture so that a hole can be drilled through the bone approximately 1 cm from its fractured end (Fig. 16-9, A). The plate is placed over this hole in order that the screw length can be measured taking into account the thickness of the plate (Fig. 16-9, B). The hole is then measured and tapped through both cortices using the 4.5-mm threaded tap (Fig. 16-9, C). The correct length screw is chosen and inserted, loosely attaching the plate to the bone. The fracture is then reduced and secured with the bone-holding forceps after the plate is aligned with the long axis of the bone. A 3.2-mm hole is drilled, using the guide for the tension device, followed by application of the tension device using a pretapped hole, usually in only one cortex (Fig. 16-9, D and E). The tension device is tightened slightly to align the plate with the long axis of the bone and to approximate the ends of the fracture fragment. The tension device should not be tightened completely at this time. The remaining holes are drilled through the plate in the fracture fragment where the first screw was placed using the proper drill guide. These holes are drilled, measured, and tapped as previously described. The screws are inserted and tightened completely (Fig. 16-9, F). After tightening the first screw, which was loosely inserted, the tension device is tightened completely with a socket wrench then with an open-end wrench if necessary (Fig. 16-9, G). Now the holes are drilled, measured, tapped, and the screws inserted individually and tightened in the fracture fragment held by the tension device (Fig. 16-9, H). After loosening and removal of the tension device, the remaining screw holes at the end of the plate are drilled, measured, and tapped and the screws are inserted (Fig. 16-9, I).

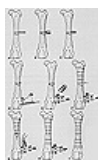


FIG. 16-9 Application of a round-hole compression plate. (A) A 3.2-mm hole is drilled through the cortex, approximately 1 cm from the fracture line. (B) The hole is measured using the depth gauge. (C) The hole is tapped. (D) The guide for the tension device is applied. (E) The tension device is used to align and stabilize the fracture. (F) The screws are placed and tightened in the fragment opposite the tension device. (G) The tension device is tightened, applying compression to the fracture. (H) The remaining open holes are filled with screws. (I) All the screws are placed after the tension device is removed.

OUTSIDE DIAMETER OF SCREW	SCREW TAP SIZE	CORE OF SCREW	DRILL BIT (PLATE HOLE)	DRILL BIT (SLIDING HOLE)	PLATE
1.5 cortical	1.5	1.0	1.1	1.5	Mini
2.0 cortical	2.0	1.3	1.5	2.0	Small Fragment
2.7 cortical	2.7	1.9	2.0	2.7	Cut
3.5 cortical coarse thread	3.5	1.9	2.0	3.5	Dog
3.5 cortical fine thread	3.5	2.4	2.5	3.5	Dog
4.0 cancellous	4.0	1.9	2.0	N/A	Dog
4.5 cortical	4.5	3.0	3.2	4.5	Standard narrow or broad
6.5 cancellous	6.5	3.0	3.2	N/A	Standard narrow or broad

* All measurements are in millimeters.

TABLE 16-1 Implant Guide

The dynamic compression plate (DCP) can be used in the same manner as described previously for the round-hole plate. It can, however, also be used as a self-compressing plate, since the round holes have been replaced with oval ones that contain an inclined plane, which allows the screws to produce plate translocation upon tightening. In this case, the 3.2-mm hole is drilled through the bone approximately 1 cm from the fractured end as before and measured with the plate in place (Fig. 16-10, A and B). It is tapped, and a 4.5-mm cortical screw of proper size is inserted until it begins to engage the hole of the plate (Fig. 16-10, D). The fracture is reduced and held with the bone-holding forceps so that the plate is aligned

parallel to the long axis of the bone. Sliding the plate across the bone (translocation of the plate) will cause the screw head to engage the oval hole of the plate at its far edge away from the fracture site. A hole is then drilled through the bone using the 1-mm load guide in the screw hole nearest the fracture site in the other fracture fragment (Fig. 16-10, D). This hole must be drilled using the yellow load guide with the arrow of the guide pointed toward the fracture site (Fig. 16-10, D). This is important, since the load guide contains an eccentrically placed hole that will allow the screw being used to compress the fractured bone end by translocation of the plate. This hole is measured, tapped and a screw of the proper size inserted. The bone clamp is removed, and upon tightening both of these first screws alternately the fracture gap is closed and the fragments reduced with good stability (Fig. 16-10, E). The remaining holes on both sides of the fracture site may be drilled using the green neutral drill guide (Fig. 16-10, F). This drill guide has the hole in the center and causes additional loading of the fracture site since the screw is placed 0.1- mm up the incline hole, thereby adding to the compressive effect. In this way, all the screws placed in the plate are loaded at least to some degree. The holes are measured, tapped, and the screws inserted. Alternate tightening of the screws from the center outward to ensure that all screws are tight is necessary (Fig. 16-10, G). This procedure should be repeated two or three times, since movement of any one screw may cause plate translocation and hence loosening of another screw.

MECHANICS

Although the application of a plate may seem simple, it is necessary to understand how the plate functions in order that optimal strength and stability of the internal fixation can be achieved. Compression plates come in a variety of sizes and designs. The larger the plate, the stiffer and stronger it will be. Plates used for internal fixation are strongest in tension or compression and weakest in bending. Plate fixations are also weak in torsion; however, this weakness is not related to the plate itself but to its fasteners, the screws. When using a compression plate, the objective is to place the plate on the tension side of the bone, that is, the side of the bone that under physiologic conditions of weight bearing would normally be subject to tensile forces.

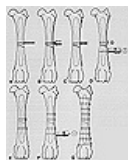


FIG. 16-10 Application of a dynamic compression plate. (A) The first hole is drilled approximately 1 cm from the fracture site. (B) The hole is measured with the contoured plate in place. (C) The hole is tapped. (D) The second hole is drilled in the other fracture fragment with the eccentric "load" guide. (E) The hole is measured, tapped, and the screw inserted, thereby reducing and stabilizing the fracture. (F) The remaining screws are placed after drilling the holes with the "neutral" guide. (G) All holes are filled with screws. Note that the dynamic compression plate allows one additional screw.

When a plate is applied under tension, the ends of the bones are approximated in compression and a stable fixation is achieved. The term "compression plate" is actually a misnomer, since the plate is placed under tension to compress the bone. Normal weight bearing provides additional tension in the plate and additional compression in the bone, thereby leaving the plate in its strongest position and allowing the transmission of weight-bearing forces through bone, which should stimulate remodeling. If a plate is left in compression, a gap may exist in the fractured bone, a condition that would allow cyclic bending of the plate during weight bearing, which could lead to catastrophic failure of the fracture fixation. Therefore, the plate should be loaded under tension whenever possible in order to prevent plate failure. The tension band surface in the dog is thought to be on the lateral aspect of the femur, the cranial lateral aspect of the tibia, the anterior aspect of the humerus, the anterolateral aspect of the radius, and the caudal aspect of the proximal ulna. Areas that may remain in doubt as to tension surfaces are the distal end of the humerus and the tibia. No work has been done regarding the smaller bones, the metatarsals and metacarpals. When dealing with bones from species with which one is unfamiliar, the tension band surface of the bone can be surmised by following the rules below:

The tension band side is usually opposite the side where a moment arm is present. In the femur, a moment arm is developed from the femoral head to the shaft of the bone, hence the tension band surface is at the end of that moment arm on the lateral surface of the femur. If there is a strong bowing of the bone, the tension band surface is usually on the convex surface of the bone. On straight bones without a moment arm, the tension band surface is usually opposite the side of the most muscle mass of that span of the bone in question. For example; the proximal tibia has most of its muscle on the caudal surface and lateral surface, thereby making the cranial medial surface the probable tension surface of the tibia, which has been used successfully in clinical situations for years.

Once the tension band surface of the bone is recognized, the plate is usually placed in this position unless there are reasons that mitigate against it. These reasons could include difficult surgical approach; poor soft tissue over the area in question, as may occur in an open fracture; severe comminution or a refracture such that using the tension band surface of the bone may cause added stresses of bending on the plate. Carter has shown in the dog that when plating a fractured femur with a large gap, the stresses on the plate are less if the plate is placed on the medial aspect of the femur rather than on the lateral aspect.⁽⁹⁾ Here, the plate is closer to the axis of weight bearing, thereby reducing the bending moment applied to the plate and increasing the longevity of the plate. Clinical experience is not sufficient at present to prove the efficacy of this form of treatment.

In most animal bones, the plate chosen should be as long as possible. It is necessary to have at least six cortices or three fully threaded screws on either side of the fracture site to be minimally safe when using plate and screw fixation. Eight cortices on each side of the fracture site is quite comforting. Occasionally at the end of a bone only four cortices (two screws) will be used. When this happens, external fixation should be considered as a possible addition.

Rybicki and co-workers,⁽³⁹⁾ when evaluating the equine metacarpus in plate fixation, showed that the longer the plate the stronger the fixation. This effect seemed to be that of distributing the load of weight bearing over a greater amount of plate-bone composite, thereby increasing the capacity of the structure. It seems relatively important in animals that are subjected to early weight bearing that the structure be as strong as possible initially. This can be accomplished by using plates that extend over the majority of the diaphysis. One problem with a plate that ends in the middle of the diaphysis appears to be

the relationship between bone-plate composite stiffness and the corresponding stiffness of the bone. Fractures can result at the end of the plate-bone junction, especially when the plate ends in the middle of the diaphysis. When possible, it is best to continue the plate into the metaphyseal area so that the inertial properties of the bone in question are larger and can absorb the change in stiffness from the implant-bone composite. The ending of an implant near a joint allows the bending stress to be absorbed through motion of the joint rather than being taken up by the bone itself. The plate is held against the bone by multiple screws. The purpose of the screws is to compress the plate against the bone, increasing the friction between the bone and the plate and thus preventing relative motion between them. This compressive force exerted by the screw along its axis is used to provide the bone-plate friction, which can be up to 37% of the axial force generated by the screw.⁽¹⁵⁾ Therefore, the greater the number of screws used, the more bone-plate friction is generally available to prevent motion at the fracture site, a fact that points out the theoretic advantage of the longer plate. The function of the screw is to provide the bone-plate friction that is accomplished when the screw is under tension loading. If misused, screws can be subjected to bending or shearing forces that will cause breakage and result in collapse of the internal fixation. To obtain these high bone-plate frictional forces and to protect the screws from bending or shear loads, the plate must be contoured exactly to the surface of the bone on which it is applied. ⁽¹⁵⁾ As described previously, this contouring is done at the time of surgery using a bending iron or press. While it is important to bend the plate adequately to conform to the surface of the bone, repetitive bending is contraindicated because it may predispose the plate to failure. Gentle bending in only one direction may work to harden the material and may actually slightly increase its strength. For perfect contouring, a slight twist of the plate may be necessary as well. This may be accomplished best using bending irons in combination with the bending press. When the plate is perfectly contoured to the bone, the screws can exert their axial compression to provide a uniform distribution of the load through the plate on the bone.

The use of axial compression with the plate is helpful only when the two ends of the bone are transverse. Simple middiaphyseal transverse fractures are usually handled by methods other than plate fixation. Therefore it is important to be able to provide interfragmentary compression with plate fixation in comminuted fractures. This is usually done with interfragmentary screws as discussed above. These screws may be placed through the plate as well as in the bone alone. In this way, the gliding hole is drilled in the ciscortex beneath the plate and the threaded hole established in the transcortex. When the screw is inserted into the plate, the fracture fragment can be compressed through interfragmentary compression. The use of lag screws is one of the most important concepts in plate fixation, since interfragmentary compression yields high frictional forces at fracture surfaces, which causes stability. Stable internal fixation allows early mobilization, weight bearing, and union of the fracture.

If a straight plate is applied to a straight bone and compressed, there is usually some deformation in the bone-plate structure such that there is a small area of contact beneath the plate with very high compressive forces followed by a decreasing stress field moving toward the transcortex until there may even be a gap on the transcortex opposite the plate⁽³⁾ (Fig. 16-11, A). If such a fixation is achieved, weight-bearing stresses usually cause cyclic closing of the fracture surface and may potentially produce bone resorption and nonunion. To prevent the occurrence of this slight gap, prebending of the plate should be uniformly practiced:^(15,31) When motion occurs at the fracture site after plating, bone resorption and nonunion of the fracture, as well as implant failure, may result. Bagby and Janes first suggested the prebending of the plate to protect the fracture gap opposite the plate.⁽⁴⁾ This solution has been demonstrated in vitro in studies by Perren, Hayes,⁽³³⁾ and Aeberhardl that showed that prebending greatly increases the structural integrity and stability at the fracture site. Nunamaker and Perren⁽³¹⁾ showed that the effect of prebending on fracture healing is also demonstrable in vivo. Prebending can be used only if contact of the transcortex can be achieved.

To perform prebending, the plate is first contoured to the bone as described above. Following this, a small kink is made directly over the fracture site so that when the plate is applied, the transcortex surfaces come in contact before the ciscortex surfaces. In this way, as the plate is applied to the bone, the plate is elastically straightened, providing good stability underneath the plate on the ciscortex and opposite the plate on the transcortex. The amount of the kink or elevation of the plate at the fracture site is dependent on the cross-sectional area of the plate involved and the length and size of the injured bone (Fig. 16-11, B). Very slight overbending of the plate will result in uniform stress distribution across the fracture site.⁽¹⁵⁾ The lack of pre-bending at the fracture site may explain the failure of seemingly adequate internal fixation using plates and screws. Since such a slight prebending will provide stability to the fracture site, a slight underbending may cause significant motion, allowing the implant to fail or the fracture to result in nonunion. In the femur of a large dog, prebending may be as large as 1 mm to 1.5 mm and still allow the plate to elastically straighten when the screws are applied for fixation. When comminution is present on the side opposite the plate, prebending is contraindicated, since it would change the axis of the bone and result in malunion or failure of the implant through bending. The most stable condition is achieved when a transverse fracture is plated with a prebent plate and an oblique lag screw is inserted through the fracture site. This is not always possible in small animals because the diameter of the bone may not be sufficient to allow an obliquely placed screw to be used as an interfragmentary screw through the plate at the fracture site.

Small gaps that are apparent in the transcortex can also be catastrophic to internal fixation with plates and screws. The reason for this appears to be that small gaps will allow micromovement that causes bone resorption and high stresses on the implant. Large gaps, on the other hand, result in the same stresses being applied to the plate, but the stress concentrations are less because more of the plate is affected by the gap. Although the relative motion may be the same, this motion will not cause resorption because of the relationship of the gap to the motion. In a small 1 mm gap, 1 mm of motion will be 100% of the gap. In a large gap that is 1 cm, 1 mm of motion would be only one tenth of the gap. It appears that motion is relative to the size of the fracture gap and that small gaps may be far more dangerous than large ones.⁽³³⁾ The fact that the surgeon often provides a bone graft in large gaps but not in small gaps underlines the misunderstanding that frequently exists. I believe that it is just as important to graft small gaps and may be even more important for the life of the implant than grafting of large gaps. This explains the high degree of success when very large gaps are bridged by cancellous bone grafts as described in Chapter 39.

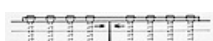
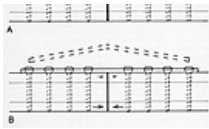
FIG. 16-11 Effects of prebending compression plates. (A) Compression applied to



a straight bone using a straight plate will give compression under the plate and a gap opposite the plate. (B) A prebent plate will provide compression on the cortex opposite the plate as well as underneath it.

FOLLOW-UP TREATMENT

Convalescence following compression-plate fixation is usually limited to restricting the patient's activity. The fractured leg is left free to be mobilized at the animal's own rate. In some fractures, such as of the elbow, early passive motion may give a better range of motion ultimately. The recent literature bears out the advantage of continuous passive motion when dealing with joint fractures.⁽⁴⁹⁾ The time interval until weight bearing usually depends on the soft tissue injury. In the dog it is not unusual for weight bearing to be resumed within 5 to 7 days following surgery. The problem with internal fixation using plates and screws is that dogs are usually walking so well and feeling so good that they may be turned loose by their owners before bony union has occurred. It is not uncommon to hear stories associated with catastrophic failure of the implant that suggest that the animal was engaged in strenuous exercise. The animal's activity should be severely restricted until there is radiographic evidence of bone healing. When plates and screws are used, radiographic evidence of healing is sometimes difficult to ascertain, since there may be little or no callus formation. Owing to this lack of callus formation at the fracture site, implant removal should be delayed until there is adequate bone remodeling across the fracture line. Bone healing occurs as either contact or gap healing when plate and screws are employed. In this mode, then, periosteal callus plays little importance in fracture healing, and the strength of the fracture is dependent on the remodeling of the bone itself. Recent studies in the dog have shown that plate removal seems to cause a decrease in bone strength for a period of 4 to 6 weeks following removal of the device. Therefore the animal's activity should be severely restricted until the remodeling phase of bone healing can be resumed to the point that the fractured leg regains its strength. Although reports in the literature seem to suggest that plate removal may be optimal at approximately 20 weeks following osteotomy in the dog, most of the animals that we have treated have been allowed approximately 3 additional months following radiographic evidence of fracture healing before plate removal.⁽²⁹⁾ In younger patients, the plates can be removed more quickly than in older patients. Although plates and screws are not used a great deal in animals with open physes, this group of animals can probably benefit from plate removal at an earlier time than an animal with a closed physis. It has been recommended that plates be removed from all animals. Our experience with compression-plating techniques at the University of Pennsylvania, which covers approximately 16 years, suggests that most plates may be left in place without serious sequelae. If problems occur, the plate may be removed at that time. Problems are usually associated with swelling or drainage from an area around the plate. Plate removal reveals that drainage originates at the junction of the plate and screw, and the screw usually is slightly loose. Following removal of the plate and screws the drainage ceases, and no further problems occur. Most of these drainages are sterile but may become infected secondarily.

Routine removal of plates and screws may lead to a refracture rate of approximately 4%. We have had very few problems associated with stress protection or plate-induced osteopenia in the dogs and cats we have treated, although such conditions are reported in the literature. Several cases of sarcoma formation at the site of old fractures have occurred with the use of plates and screws, as well as with other implants. These tumors seem to be associated with fractures that have healed poorly as a result of instability or infection. Sarcoma formation is not limited to fixation with plates and screws, since we have seen tumors in animals treated with intramedullary fixation and cerclage fixation.

ORTHOPAEDIC WIRE TECHNIQUES

Orthopaedic wiring of fractures has long been popular in veterinary medicine.⁽³⁷⁾ Use of orthopaedic wire, like all other techniques, is successful when the indications are proper and the techniques are adequate. The problems associated with orthopaedic wiring and the poor results that are sometimes obtained can usually be traced to improper technique or indications. ^(13,28,48)

FULL CERCLAGE WIRING

Full cerclage wiring has been used with presently accepted techniques for approximately 10 years in veterinary medicine.⁽¹⁷⁾ Adequate full cerclage wiring in the dog requires the use of large heavy-gauge wire of 18- or 20- gauge diameter and some method of adequately molding the wire to the bone.⁽⁴⁹⁾ One of the two most common types used is the ASIF wire loop, with its wire tightener, which was originally intended for temporary fixation of fracture fragments with the ASIF system. This technique has come to be used as a definitive method of fracture fixation in small animals and seems not to pull apart as one might suspect. The other technique is to use heavy-gauge wire and twist the wire in a fashion that allows the wire to tighten over the cortex. With this technique a wire twister or pair of pliers may be used.

INDICATIONS

Full cerclage wires can be used in long oblique fractures, spiral fractures, or in fractures that have longitudinal cracks. The wires are used most easily in middiaphyseal locations where the diameter of the bone is most constant.

TECHNIQUE

The technique of application of full cerclage wiring to bone requires that the fragments be wired in place before any intramedullary fixation is used^(48,49) (Fig. 16-12). It is often difficult to wire a comminuted fragment into position once reduction with an intramedullary pin has been made. If the bone cortices are parallel, the wire may be placed directly over the bone, but if there is any degree of flaring, some small rasping of the cortex is necessary to provide an appropriate channel for the wire so that it will not slip after being tightened. One must take great care in rasping, since defects as small as 1/16 inch in a dog's bone have been shown to decrease its strength in bending by approximately 25%.⁽²⁹⁾ Therefore deep rasping of the bone may cause failure at the area of the wire because of the technique used to apply the wire. In general, the wires should be spaced approximately 1 cm apart; one wire is rarely adequate, since it provides a fulcrum for motion. Because the vascular supply of the bone flows from the medullary cavity toward the cortex, the number of cerclage

wires does not seem to deter fracture healing. The wire should be passed around the bone and be in contact with the bone. No soft tissue should be left underneath the wire, since it would undergo necrosis and cause loosening of the wire.

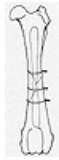

FIG. 16-12 Full cerclage wiring. Multiple cerclage wires are placed before the introduction of a Steinmann pin.

It is also important not to entrap vessels or nerves with the cerclage wire passer. Once the wire is brought around the bone to fit into the grooves as necessary, it is tightened and twisted, usually with a wire twister or pair of pliers. It is important that the wire engage itself and be twisted over itself; one wire should not be wrapped around the other (Fig. 16-13). If this occurs, the wire should be removed and replaced. Experience will determine the amount of tightening applied to the wire; it is easy to plastically deform the wire to the point that failure occurs during twisting or, worse yet, in the early postoperative period. Reports show that any amount of pressure that is achieved through the twisting process is reduced considerably when the wires are bent down to conform to the surface of the bone.(36) Thus, the wire should not be bent if this compression is desired. In cases in which the surface of the wire cannot be left in position, the wire can be cut relatively long and the top part of the wire bent down to the bone and the wire twisted at the end to prevent the negative effects of wire bending. With the ASIF wire twister, a certain amount of compression seems to be achieved and remain after the wire has been cut and fixed in place. Full cerclage wire fixation is usually inadequate by itself and must be accompanied by intramedullary fixation. Many times this fixation is in the form of multiple Steinmann pins, and the initial reduction can be accomplished with one or two small pins. After the wires have been applied completely, the rest of the pins can be inserted and the fixation completed. For full cerclage wiring to be successful, it is necessary to have perfect anatomical reduction. If this reduction is not achieved, weight bearing will result in subsequent fracture motion, which will cause loosening and failure of the implants.

FOLLOW-UP TREATMENT

Total encircling wires do not usually require removal. Sometimes the wires may cause a problem if significant muscle atrophy has occurred over the area as a result of the sharp points. When necessary these wires may be removed following fracture healing. Most other wires are incorporated in the bone and are very difficult to remove after complete fracture healing and remodeling have occurred.

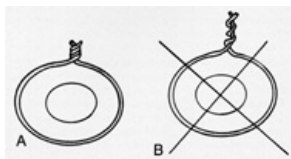


FIG. 16-13 Techniques of orthopaedic wire tightening. Proper wire tightening allows the wire to twist around itself (A) and does not allow one wire to twist around the other (B). incorporated in the bone and are very difficult to remove after complete fracture healing and remodeling have occurred.

COMPLICATIONS AND CONTRAINDICATIONS

Complications of full cerclage wiring include loosening of the wire and collapse of the fracture fragments. These complications can usually be traced to failure to adhere to the techniques described above(48,49) or to inappropriate selection of cases for wiring. I suggest that full cerclage wiring not be used with Kuntscher nailing, since the possibility of further fragmentation when the nail is driven could render the technique unusable.

HEMICERCLAGE WIRING

The use of hemicerclage wiring has been advocated by many in combination with intramedullary Steinmann pinning.(37) In this technique a large 18- or 20-gauge wire is used to hold fracture fragments or cracks together. The wire is effective in reinforcing longitudinal cracks in the cortex and often in preventing rotation and overriding of oblique fracture fragments. The wire is passed through a small hole in one fracture fragment, passes across the fracture site, and comes out through a small hole in the opposite fracture fragment. The wire is twisted together in the same manner as described in full cerclage wiring and may or may not be bent over in place, depending on its application. Sometimes the wire is also placed around the intramedullary device so that the pin is incorporated with the wire in bone-fracture fixation (Fig. 16-14). Many patterns and applications of hemicerclage wiring have been reported in the veterinary literature. They are a definite adjunct in any fracture that is handled with the single Steinmann pin when rotation of the fragments is a possibility or if overriding of the fracture is a complication.

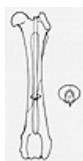

FIG. 16-14 One method of hemicerclage wiring. A hemicerclage wire is used to provide rotational stability and prevent overriding. Here it is used around the intramedullary pin.

POSTOPERATIVE CARE

Postoperative care of hemicerclage wiring is similar to that of full cerclage wiring. Even if the hemicerclage wire is wrapped around the intramedullary pin, the pin can usually be removed after healing has been accomplished. In these cases the wire may have to be removed, but in general the hemicerclage wire is left in place.

COMPLICATIONS

Most of the complications associated with hemicerclage wiring involve breaking of the wire as a result of use of too small a wire or using wire beyond its limitations.

TENSION BAND WIRING

Tension band wiring is a form of hemicerclage wiring that is usually used in conjunction with Steinmann pins to achieve stable internal fixation by opposing the pull of muscular attachments on bone. Tension band wiring or figure-of-eight wiring can also be used in a middiaphysis of bone on the tension band surface to help minimize distraction and provide increased stability in nonunions and/or initial fixation after osteotomy.

INDICATIONS

Tension band wiring has been reported in the dog and is commonly used to fix fractures or osteotomies of the olecranon, greater trochanter of the femur, patella, fibular tarsal bone, tibial tuberosity, acromion of the scapula, coracoid process of the scapula, medial malleolus of the tibia, and any other traction apophysis.

TECHNIQUE

To accomplish tension band wiring, the fracture fragments first must be reduced, usually with two pins that are parallel to each other. The pins are driven into the fracture fragment through the fracture and into the parent bone. A hole is drilled through the parent bone approximately the same distance from the fracture site as the emergence of the pins from the fractured fragment. This hole is drilled transversely, and an 18- or 20-gauge wire (depending on the size of the animal) is threaded through the hole, looped on one side, and passed in figure-of-eight fashion around the two small Steinmann pins used for initial fixation (Fig. 16-15, A). The wire is then twisted together on one side, and the loop is twisted to allow tightening of both sides of the fixation device (Fig. 16-15, B). The fixation device need not be under great tension but is used only to counteract distraction forces applied against it. It is therefore possible, when completed, to bend the wires down, since no compressive force needs to be applied through the wire per se. The ends of the Steinmann pin can either be bent over the wire and impacted into the bone or simply cut off just proximal to the wire so that the wire will not slip over the ends of the pin.

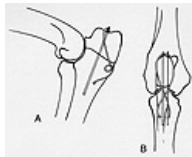


FIG. 16-15 The tension band wire. (A) The loop of the tension band wire is shown prior to tightening. (B) The tension band wire is tightened by twisting the wire and cutting off the ends.

When using a tension band wire in the middiaphysis of the bone, a transverse hole is drilled approximately 1 cm or 2 cm above and below the fracture line and the wire is passed through both holes so that it can be looped in a figure-of-eight and tightened as described above. This technique is useful in controlling motion at the fracture site, especially in cases of middiaphyseal osteotomies.

POSTOPERATIVE CARE

Tension band wires are usually left in place unless they cause problems. Devices are easily removed by making stab incisions over the pin area and extracting the pin, grasping the wire, and removing it after cutting it in two pieces.

COMPLICATIONS

Complications of tension band wiring occur when only one pin is introduced into the fracture site, allowing rotation of the fracture fragment. In this case a figure-of-eight wire rapidly fatigues and breaks, resulting in a nonunion. Other problems include pin or wire protrusion through the skin and pain associated with palpation over the device after fracture healing has been accomplished. Complications commonly result from the use of wire of too small a diameter.

EXTERNAL SKELETAL FIXATION

HISTORY

Although Parkhill (32) in 1897, may have been the first person to use external fixation with paracutaneous pins, the use of such pins with some sort of external frame for controlling the motion of fractures was found practical in veterinary medicine only after Stader's introduction of his splint (24,44,45) and Ehmer's modification of Roger Anderson's device. (2,12) Stader's device was used frequently during World War II by the United States armed forces for treatment of fractures associated with war trauma. (43) Following the war, external skeletal fixation fell into disrepute for use in humans; however, veterinary surgeons such as Jenny, Brinker, and Rudy promulgated these devices for treatment of fractures and fixation following osteotomies. (7,20,22)

Paracutaneous pin fixation in humans has recently been popularized by the use of the Vidal-Adrey frame of the Hoffmann apparatus. (18,21,23,47) This fixation system has been embraced by most European orthopaedic centers and is gaining a foothold in the United States. With the exception of certain groups in Belgium, the system is generally used for open fractures accompanied by severe soft tissue injuries and in leg-lengthening procedures. (5,20,22) The devices are not accepted in the United States for treatment of closed fractures in humans. The recent popularity of these external fixation devices has caused a sudden increase in the numbers and types of systems available through most orthopaedic supply houses. One major drawback to most of these new devices is their extremely high cost. Of the new devices presently marketed, none has been developed specifically for use in animals. The Stader splint, although extremely useful, is no longer available commercially; however, the Kirschner Company continues to manufacture the Kirschner splint, the most widely used device in veterinary orthopaedics in the United States. (35)

Current research and development of external fixation using paracutaneous pins raises hopes for an up-dated, economical system that will allow the veterinary profession to reap the rewards of continued use of external pin fixation. (10)

BIOMECHANICS

The purpose of an external skeletal fixation frame is to immobilize the fracture so that healing can take place. Current information about fracture healing indicates that relatively rigid stabilization is preferred initially to allow bony union of the fracture fragments. As the fracture matures and healing progresses, a gradual reduction in the rigidity of stabilization may be advantageous to impart strength to the healing fracture and to prevent bony resorption due to stress protection.⁽⁵⁾ Very little data are available on the optimization of the mechanics of paracutaneous pin fixation.^(5,4) The following represents a practical guide to effective immobilization of fractures through the use of an external fixation device.

Half-pins, as they have been used in both human and veterinary orthopaedics for the last 40 years, although adequate in most small animal fractures, are the weakest and least stable method of external skeletal fixation. Full-pin fixation or through-and-through pinning with connecting bars on both sides of the fracture increases the strength of the fixation approximately fourfold. Results with half-pins have been greatly improved by the use of an adequately threaded shaft on the pin so that it has a good purchase in the bone. Predrilling the hole allows the use of a threaded pin in hard cortical bone of animals. To ensure correct placement of the pins when using a half-pin splint, the proximal and distal pins are positioned as far away from the fracture site as possible, and the middle pins (near the fracture site) should be positioned as close to the fracture site as possible (Fig. 16-16) as determined by the quality of the soft tissues and the bone itself. The stability of the half- and full-pin devices is related to the pin diameter that penetrates the bone and the distance from the bone that the connecting bar is applied; the larger the pin diameter (up to approximately 30% of the diameter of the bone), the stronger the fixation (fourth power function). The greater the distance the connecting bars are applied away from the bone, the less rigid the fixation becomes. This increasing distance from the bone is not linear, but has a third-power relationship. Use of half-pin splints for fixation of fractures shows a relative weakness of bending in most planes.



FIG. 16-16 Half-pin fixation. This drawing shows the pin relationships in a half-pin frame.

Full-pin splintage with connecting bars on both sides of the leg is very stable in varus/valgus bending motion but is relatively weak in anterior/posterior bending motions. Triangulation splinting, that is, using a full-pin splint with side bars on both sides of the leg plus an anterior half-pin device connected to the medial and lateral frames, can increase anterior/posterior bending rigidity considerably. A common complication when using full-pin fixation is the sliding of the pins in the medial-lateral direction. This can be eliminated by the use of at least one threaded pin, the threads of which engage the bony cortex on each side of the fracture site; oblique angulation of smooth pins will also help to limit the sliding motion (Fig. 16-17). The ultimate strength of the external fixation device can be influenced by the number of pins in each fracture fragment. There seems to be an increase in stability up to and including four pins in each fragment.⁽⁵⁾ In all situations, the most proximal and distal pins are the most highly stressed. Again, when using full-pin splinting, it is important to place the pins as far from and as near to the fracture as possible. If the bones are sufficiently long, three or four may be used in each fracture fragment.

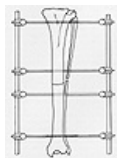


FIG. 16-17 Full-pin fixation. The full-pin splint is shown with a threaded pin in each fragment to prevent medial-lateral sliding of the device.

APPLICATION OF KIRSCHNER-EHMER APPARATUS

The Kirschner half-pin splint can be applied with either a single connecting bar as popularized by Brinker or with two triangular half-pin units assembled by means of a double clamp and connected with a single bar.⁽¹⁸⁾ Ideally it is advisable to insert the paracutaneous pins after reduction of the fracture is accomplished, to allow insertion of the pins through the skin in a site that will be without tension after the apparatus is assembled. If reduction of the fracture is impossible prior to pin introduction, an effort should be made to position the pin through the skin where it will remain after the fracture is reduced. Tension on the skin may result in a skin complication.

When using the single connecting bar to hold all the paracutaneous pins, the proximal pin is placed first, followed by the distal pin. Four single fixation clamps are threaded on the rod of which the proximal and distal clamps go through the paracutaneous pins. The two middle pins, one in each fragment, are then inserted through the single fixation clamp and into the bone. When using the half-pin splint, it is recommended that the paracutaneous pins in each fragment be placed at an angle 35° to 40° or greater in relation to each other. This helps prevent the pins from pulling straight out of the bone. For various reasons, it may be difficult to line up all the half-pins, thereby allowing a single bar to be used. With this complication, the two pins in each fragment may be connected with a bar with a single fixation clamp. A double fixation clamp is then placed between the two pins on the bar so that an additional bar may connect the proximal and distal bars, providing stability to the fracture. This method of fixation requires the least amount of sophistication in pin placement and results in the same type of fixation but with additional bulkiness of the external frame. When using this technique, two connecting bars can be used to increase strength.

Transfixation pinning may be accomplished in the same manner described previously, with the exception that pins are placed perpendicular to the long axis of the bone and are seen parallel to one another in the anterior-posterior plane. Considerable angulation may occur in the transverse plane, and either single bars or the traditional three-four bar arrangement may be used for connecting the fracture fragments. Using a single bar, the proximal and distal pins are placed first and connected to long bars with the appropriate number of single fixation clamps on both sides of the fracture site. The fracture is then reduced, and the single fixation clamps on both sides can be tightened. Using two or more additional single fixation clamps on each bar that has been preplaced before reduction of the fracture, an additional transverse pin may be

drilled across the fracture site aligning with the opposite bar. Care must be taken that these pins are drilled on the same plane as the original two pins so that when they emerge from the opposite side of the bone they may also be incorporated in the single bar. Since the single fixation clamp has a great deal of movement, it can adjust for small discrepancies in position. If the pins used in transfixation pinning are parallel, it is common for the pin to slide back and forth through the fracture plane following several weeks of fixation. To eliminate this problem, threaded pins are used initially. These threaded pins are available in the proper size for use in the Kirschner splint, although they are not supplied from the Kirschner Company. An extra half-pin mounted anteriorly and attached to both lateral side bars may be of advantage in creating additional strength against bending in the cranial-caudal direction if used in both fragments and connected by a longitudinal bar. Adjustment of the fracture and final tightening may be accomplished at the end of surgery, preceding closure of the wound. Additional adjustments can be made following radiographic evaluation.

INDICATIONS

Most closed fractures can be treated with forms of fixation other than external pin fixation, thereby eliminating problems of pin tract care and a bulky external frame. In general, the external frame works much better when the pins pass through tissue that does not move relative to the pins. Therefore, indications for external fixation in the dog are the tibia and radius and ulna, where there is very little contracting muscle between the frame and the bone itself. The devices have been used in the humerus and femur, but it is important to attempt pin placement where there is little movement of soft tissue beneath the pins. The external frame is used advantageously in third-degree open fractures when large amounts of soft tissue or bone are lost or mutilated and in chronic osteomyelitis where surgical intervention requires removal of bony sequestrum, sometimes leaving defects or large gaps. Wound treatment is facilitated by the use of external pin fixation, since wounds can be treated without displacing or mobilizing the fracture fragments. When treating such fractures with external casts or splints, the removal of the cast allows movement to occur at the fracture site. This continued movement may be detrimental to fracture healing and the return of vascularity to the fracture fragments.

COMPLICATIONS

PIN TRACT SEQUESTRA

Pin tract sequestra have been reported to be a result of faulty technique, that is, thermal necrosis produced by drilling the pin through the bone, although this etiology has not been proven. A sequestrum, if present, is usually treated by surgical removal.

Local infections of the pin tract can occur with the use of paracutaneous pins. The infrequency with which these infections occur does not lessen the fact that they are more easily prevented than treated. Prevention of pin tract infections is related to the stability of the pin in the bone. If the pin is tight in the bone, pin tract infections are relatively uncommon. Once the pin loosens, the only treatment for the infection is removal of the pin. Tension on soft tissue or motion of soft tissue relative to the pin is also an origin of pin tract infection. Careful placement of the pin so that there is no tension in the skin and minimal muscle tissue penetration will help alleviate this problem. One method of preventing loosening of the pin is the use of threaded pins. In this context, we refer to pins with a threaded diameter that is larger than the diameter of the pin itself, not the threaded Steinmann pin where the thread has been cut into the outside diameter of the pin, thus producing very little fixation effect. These threaded pins, which are compatible in diameter to the Kirschner-Ehmer apparatus, are available from other manufacturers.

LOOSENING OR DISENGAGEMENT OF A HALF-PIN SPLINT

Loosening of the splint itself can occur when one side disengages from its fracture fragment. This is usually caused by inappropriate placement of the pins at an angle of less than 35° such that the pins themselves are free to move, but it may be due to loosening of the single fixation clamps, thus allowing movement of the paracutaneous pin. Constant checking of the single and double fixation clamps is necessary to maintain the stability of the device.

With half-pin splinting, bending of the device may occur depending on the amount of weight bearing by the patient. The single fixation clamps are now made with aluminum U-shaped parts, which are often found to be fractured on reexamination of the patient. The U part must be changed and replaced to prevent the device from loosening. Often, it is helpful to use an acrylic around the entire single fixation clamp to prevent loosening of the device. The simple addition of this acrylic can extend the stability of the splint several months.

BENDING OF THE TRANSFIXATION PINS

Bending of the transfixation pins is a complication of too much weight bearing or insufficient number or size of pins penetrating the cortex. If the pin is not badly bent, movement of the pin's single fixation clamp on the longitudinal bar may be adequate to provide restabilization of the fracture fragments. If this is not possible, the bent pin should be exchanged for a straight one. Additional pins may be placed to prevent the overload failure that is occurring in the system.

Controversy exists in the current literature as to the method of insertion of pins and the care given to the pin tract for the duration of the external pin fixation,⁽⁵⁾ specifically, whether a skin-relieving incision should be made before penetration of the pin through the soft tissue. The proponents of skin-relieving incisions insist that this reduces the tension on the skin and therefore alleviates later problems with pin tract infection. Opponents of such incisions state that if the pin is placed properly in such a way that the skin is not under tension, the skin-relieving incision is unnecessary. Care of the pin tracts requires cleanliness. Whether antibiotic preparations or ointments as well as bactericidal solutions may be helpful in preventing infection has not been well documented in the literature. In most animal applications, soft bandaging materials are used to cover the entire fixation device to help keep the pin-skin junction clean as well as to prevent the entire apparatus from becoming caught on objects such as screen doors, cage doors, and furniture.

PIN REMOVAL

Removal of pins following fracture healing is accomplished by disassembly of the frame and extraction of the pin. Pin

removal may often be done by finger traction. Threaded pins may be more difficult to remove and may require a bone chuck or grasping instrument. Generally pins can be removed under sedation without general anesthesia.

REFERENCES

1. Aeberhard HJ: Der Einfluss der Plattenüberbiegung auf die Torsionsstabilität der Osteosynthese. Thesis, Bern, Switzerland, 1973
2. Anderson R: An automatic method of treatment of fractures of tibia and fibula. *Surg Gynecol Obstet* 58:639, 1934
3. Askew MJ, Mow VC: Analysis of the intraosseous stress field due to compression plating. *J Biomech* 8:203, 1975
4. Bagby GM, Janes JM: The effect of compression on the rate of fracture healing using a special plate. *Am J Surg* 95:761, 1958
5. Booker AF, Edwards CC: External fixation: The current state of the art. Proceedings of the Sixth International Conference on Hoffmann External Fixation. Baltimore, Williams & Wilkins, 1979
6. Brinker WO: The use of intramedullary pins in small animal fractures. *North Am Vet* 29:292, 1948
7. Brinker WO, Flo GL: Principles and application of external skeletal fixation. *Vet Clin North Am* 5:197, 1975
8. Brinker WO, Hohn RB, Prieur WD: Manual of Internal Fixation for Small Animals. New York, Springer-Verlag, 1983
9. Carter DR, Vasu R, Hams WH: Altered stress fields created by the application of different fracture plates to the canine femur. Transactions of Fourth Annual Meeting of American Society for Biomechanics, 1980
10. Charnley JC: Positive pressure in arthrodesis of the knee joint. *J Bone Joint Surg* 30B:478, 1948
11. Ehmer EA: Bone pinning in fractures of small animals. *J Am Vet Med Assoc* 110:14, 1947
12. Ehmer EA: Traumatic injuries in small animals. *J Am Vet Med Assoc* 112: 246, 1948
13. Ellison GW, Piermattei DL, Wells MK: The effects of cerclage wiring on the immature canine diaphysis: A biomechanical analysis. *Vet Surg*, 11:44, 1982
14. Fackelman GE, Nunamaker DM: Manual of Internal Fixation in the Horse. New York, Springer-Verlag, 1982
15. Hayes WC, Grens WB, Murch SA et al: Effects of plate modulus, thickness and prebending on the mechanics of compression plate fixation. Transactions of the 24th Annual Orthopaedic Research Society, 1978
16. Hayes WC, Perren SM: Plate-bone friction in the compression fixation of fractures. *Clin Orthop* 89:236, 1972
17. Hinko PJ, Rhinelander FW: Effective use of cerclage in the treatment of long bone fractures in the dog. *J Am Vet Med Assoc* 166:520, 1975
18. Hoffmann R: Rotules a os pour la reduction dirigee, non sanglante, des fractures. In *Congres Francais de Chirurgie*, 601-610, 1938
19. Jenny J: Kuntscher's medullary nailing in femur fractures of the dog. *J Am Vet Med Assoc* 117:381, 1950
20. Johnson HF, Stovall SL: External fixation of fractures. *J Bone Joint Surg* 32A:466, 1950
21. Jorgensen TE: Measurements of stability of crural fractures treated with Hoffmann Osteotaxis: II. Measurement on crural fractures. *Acta Orthop Scand* 43:207, 1972
22. Karlstrom G, Olerud S: Subcutaneous pin fixation of open tibial fractures. *J Bone Joint Surg* 57A:915, 1975
23. Karlstrom G, Olerud S: Stable external fixation of open tibial fractures: A report of five years of experience with the VidalAdrey double frame method. *Orthop Rev* 6:25 1977
24. Lewis KM et al: The Stader reduction splint for treating fractures of the shaft of the long bones. *Ann Surg* 116:623, 1942
25. Maden JR: External skeletal fixation in the treatment of fractures of the tibia. *J Bone Joint Surg* 34A:586, 1949
26. Matthews LS, Hirsch C: Temperatures measured in human cortical bone when drilling. *J Bone Joint Surg* 54A:297, 1972
27. Muller ME, Allgower M, Schneider R et al: Manual of Internal Fixation. New York, Springer-Verlag, 1979
28. Newton CD, Hohn RB: Fracture nonunion resulting from cerclage appliances. *J Am Vet Med Assoc* 164:593, 1974
29. Nunamaker DM, Hayes WC, Schein S et al: Mechanical properties of healing fractures following removal of compression plate fixation. Transactions of the 28th Annual Meeting of the Orthopaedic Research Society, 1982
30. Nunamaker DM, Perren SM: Force measurements in screw fixation. *J Biomech* 9:669, 1976
31. Nunamaker DM, Perren SM: A radiological and histological analysis of fracture healing using prebending of compression plates. *Clin Orthop* 138: 167, 1979
32. Parkhill C: A new apparatus for fixation of bones after resection and in bones with a tendency to displacement. *Trans Am Surg* 15:251, 1897
33. Perren SM: Physical and biological aspects of fracture healing with special reference to internal fixation. *Clin Orthop Rel Res* 138:175, 1979
34. Perren SM, Hayes WC: Biomechanik der Plattenosteosynthese. *Mgd Orthop Technik* 94:56, 1974
35. Pettit GD: Kirschner fixation splint. *Kirschner Catalogue*, 80-1, 1980
36. Rocks RL, Tarvin GB, Pijanowski GJ et al: In vitro cerclage wiring analysis. *Vet Surg* 11:39, 1982
37. Rudy RL: Principles of intramedullary pinning. *Vet Clin North Am* 5:209, 1975
38. Rush LV: Atlas of Rush Pin Technics. Berivon, 1959
39. Rybicki EF, Simonen F, Mills EJ et al: Mathematical and experimental studies on the mechanics of plated transverse fractures. *J Biomech* 7:377, 1974
40. Salter RB, Simmonds DF, Malcom BW: The biological effect of continuous passive motion on the healing of full-thickness defects in articular cartilage. *J Bone Joint Surg* 62:1932, 1980
41. Seligson D, Pope MH: Concepts in External Fixation. New York, Grune & Stratton, 1982
42. Sequin F, Texhammar R: AO/ASIF Instrumentation. New York, Springer-Verlag, 1981
43. Shar CM, Kreuz FP Jr, Jones DT: End results of treatment of fresh fractures by the use of the Stader apparatus. *J Bone Joint Surg* 26:471, 1944
44. Stader O: A preliminary announcement of a new method of treating fractures. *North Am Vet* 18:37, 1937
45. Stader O, Lewis KM: The Stader reduction splint for treating fractures of the shaft of long bones. *Ann Surg* 116:623,

1942

46. Stone EA, Betz CW, Roland GN: Effects of Rush pins on the distal femoral growth plate of young dogs. Am J Vet Res 42:261, 1982

47. Vidal J, Rabischong P, Bonnel F et al: The study of biomechanics of the external fixture of Hoffmann in fractures of the leg. Montpellier Surg 16:53, 1970

48. Withrow JJ: Use and misuse of full cerclage wires in fracture repair. Vet Clin North Am 8:201, 1978

49. Withrow JJ, Holmberg DL: Use of full cerclage wires in the fixation of 18 consecutive long bone fractures in small animals. J Am Anim Hosp Assoc 13:735, 1977
