

Bovine Castration

Castration Defined:

Castration of a bull (male) calf is the process of removal or destruction of the testicles. A steer is a castrated male calf raised for beef.

Bovine Castration Overview:

- Physical: surgical removal of testes and epididymis, rubber-ring castration, the crushing of spermatic cords (Burdizzo method)
- Hormonal: immunisation against gonadotrophin-releasing hormone (GnRH)
- Chemical: injection of toxic substance into testes.

Reasons for Castration:

Reasons given for castrating beef calves include to:

- stop the production of male hormones and semen
- historically, tame oxen for draught purposes
- prevent mating and reproduction after the age of puberty
- produce docile cattle that are easier to handle compared to bulls
- decrease aggressiveness, mounting activity, injuries, frequency of dark-cutting carcasses
- enhance on-farm safety for animals, producers and employees
- decrease costs associated with fencing and handling facilities compared to bulls
- avoid discounted price that packers pay for bull carcasses
- provide meat products of the quality consumers demand

Castration Age:

Castration at a young age minimizes hazards to the calf, the cow-calf producer and the feedlot owner. Hazards for calves and owners include:

- sickness or death of calves following castration at an older age
- decreased liveweight gains (productivity) in the weeks following castration of older calves

Many producers choose to castrate new-born calves because:

- techniques are easier for the operator

- castration is less stressful on newborn calves
- concerns for animal welfare related to castrating older calves

Although there is no evidence that pain differs between young and older calves, there is less risk with castration of young calves.

Restraint:

The younger the calf, the easier it is for you to restrain it. Calves older than a month of age require two people to restrain it. However, one person can effectively restrain a one-week-old calf and do all the necessary operations.

If you have access to a calf table, use this instead as it greatly simplifies your job that you have to do.

Use a chute with older animals, preferably one with a head-gate attached.

If there is no chute available, an animal may be tied to a fence with a halter, with your assistant pushing the calf to the fence, then applying a tail-jack. Tail-jacking immobilizes the rear-legs of the calf and thus it cannot kick. This will not stop a calf from flinching and jerking when a scalpel is cut into its scrotum!

Preoperative Considerations:

Tetanus vaccination and antimicrobials important (environment)

Anaesthesia and Pain Relief:

Choices in anaesthesia and pain relief include:

- short-acting, local anaesthetic (e.g. lidocaine) with an effect for about 45-90 minutes
 - an epidural injection designed to block pain in the hind quarters and testicular region
 - local injections into the testicles, incision site or spermatic cord
- alpha-2 agonist (xylazine) given alone or in conjunction with a local anaesthetic will provide analgesia for a few hours
- non-steroidal anti-inflammatory drugs (NSAIDS) such as ketoprofen used alone, with local anaesthetics or with xylazine

Castration Methods:

Castration may be accomplished by physical, chemical or hormonal techniques. Physical methods are most common. Testicles may be removed surgically or killed by obstructing the blood supply. Young calves may be castrated with rubber rings, Burdizzo or by surgery. Surgical castration may be more appropriate for calves that are not handled until weaning.

✚ Elastic Band Castration

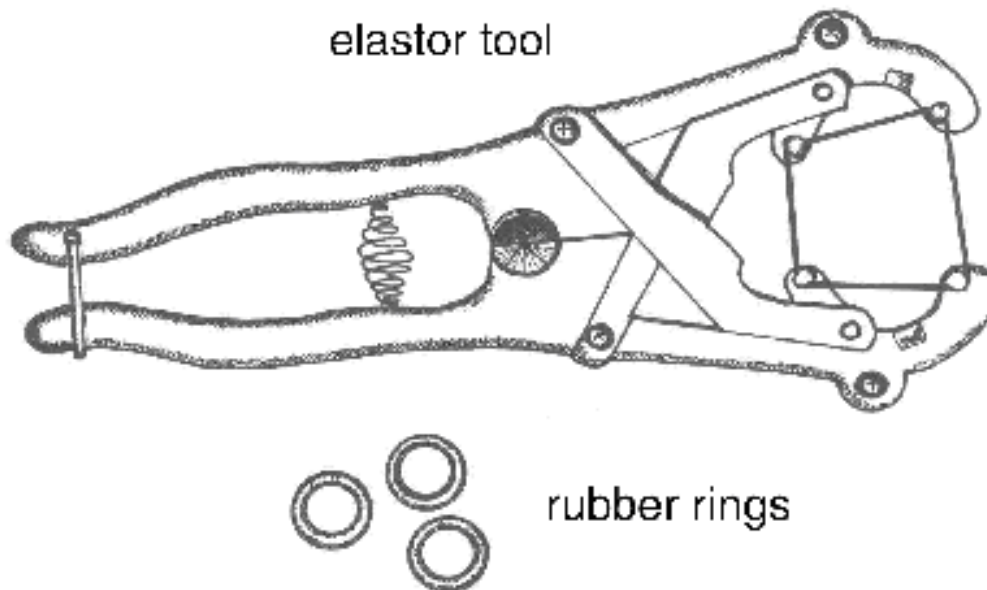


Figure 1. Elastrator tool used to apply rubber rings.

Elastic band castration cuts off blood supply to the testicles. A lack of blood supply kills the testicles. The equipment for banding calves less than three weeks of age is called an elastrator. An elastrator (Figure 1) is the tool used to apply an elastic band to the neck of the scrotum. The elastic band obstructs blood flow to the testicles and the scrotum. In time, the scrotum and testicles fall from the body. The elastrator band is most reliable for calves less than three weeks of age. EZE and Callicrate are tools used to band older, larger calves with latex bands. Vaccination to protect against tetanus and blackleg is recommended. These infections may be more common when older calves are banded. Vaccines must be given weeks in advance of banding. Researchers from Saskatchewan provide strong evidence against using elastic band or surgical castration of mature bulls based on pain response, time to heal and post-castration weight loss. Researchers from Alberta found no advantage in average daily gain with late castration with latex bands vs. surgical castration.

Faulty application of elastic bands results in retention of a testicle and calves with a bull-like appearance (stags). To successfully use elastic bands, the operator must understand the anatomy and restrain the calf properly. Some European countries have banned elastic band castration because officials consider it inhumane.

Technique

1. Use the elastrator technique for calves from birth to three weeks of age.
2. Use elastic rings purchased within the last 12 months to avoid breakage and assure a tight fit. The rings must be strong enough to cut off blood flow in the arteries as well as the veins. If not, the scrotum will swell.
3. Pull both testicles into the scrotum. A muscle attached to each testicle will be pulling against you.
4. Place the rubber band on the elastrator. Hold the elastrator with the prongs facing up. Close the handles to open the band.
5. With the calf standing and both testicles in the scrotum, stretch the ring open and slip the open band up over the scrotum. Release the band just above the top of the testicles (~0.5 cm), not at the base of the scrotum.
6. Check to be sure both testicles are still in the tip of the scrotum and that the ring is placed properly (Figure 2). If not, cut the ring with scissors and start again.
7. Remove the elastrator from under the band.
8. EZE or Callicrate bands are applied in a similar location. See the manufacturer's literature for detailed instructions.

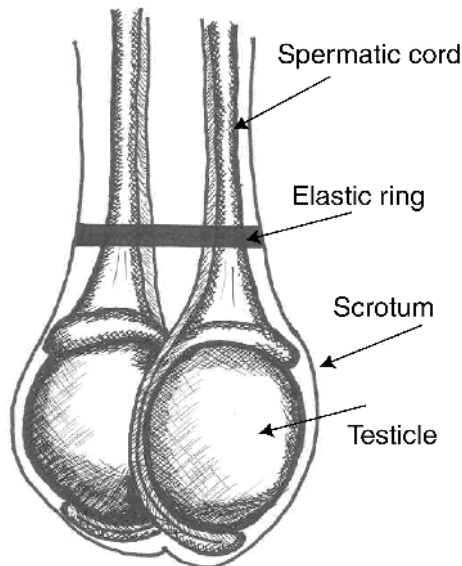


Figure 2. Elastic band at top of testicles.

Pain:

- local anaesthesia virtually eliminates the acute pain caused by rubber-ring or latex-band castration
- acute pain caused by banding is greater than that caused by
- Burdizzo clamps

Advantages and Disadvantages:

- bloodless, easy to perform
- large lesions may form above the band site and persist for long times, making latex bands inappropriate for yearling cattle
- wounds heal more slowly than those from surgical castration
- newest versions of banders for older calves adjust the latex bands to correct tension
- potential for missed testicles
- band may break or band may not disrupt all circulation to the testicles
- preferred for castrating at a wet, muddy feedlot
- infections, including tetanus and blackleg, may warrant vaccination prior to banding
- public concern about pain and animal welfare associated with banding older calves
- lower weight gains following latex-band castration compared to surgical castration
- EZE and Callicrate methods without anaesthesia for older bulls deemed inhumane and unethical

Short-Banding Bulls

This method of rendering a bull infertile was developed at the New Mexico Station in the 1980's. It does not remove any part of the bull's genitals, but it does make him a pseudocryptorchid because the testes are forced near the abdominal wall. However, this does not make the bull a steer, as it does not get rid of the hormones, temperament or sexual urges of the animal. This can make such an animal a likely candidate as a Gomer Bull for females that are going to be artificially inseminated. The methods of such a procedure are as follows:

1. Restrain the calf
2. Force the testes up so that the bottom third of the scrotum is available.
3. Press this portion of the scrotum through the rubber ring, then release the ring.

Burdizzo Clamps for Castration

The Burdizzo method crushes the blood vessels, interrupts the blood supply to the testicle and thus kills the testicle. Good restraint is essential because the Burdizzo must be in place about 10 seconds to crush the artery.

The Burdizzo (Figure 3) must be in good condition. The jaws must be parallel and close uniformly across their width so pressure will be evenly distributed across their length. Leave the Burdizzo slightly open when not in use.

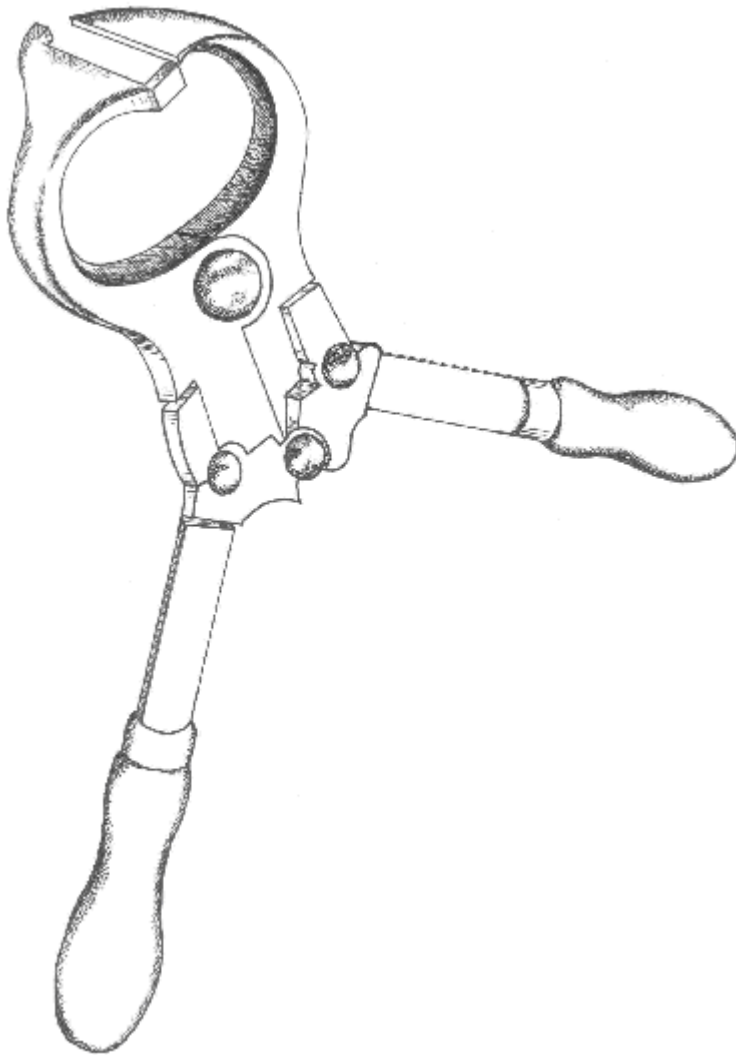


Figure 3. Burdizzo clamp.

Technique

1. Use this technique when the spermatic cord can be palpated - one month and older.
2. Choose and use the proper sized forceps for the size of animal. With undersized forceps, there will be too much tissue between the jaws and there will not be enough force to properly crush the arteries.
3. Find the spermatic cord on one side of the scrotum. Reach between the hind legs and grasp the scrotum above the testicles. The spermatic cord runs from the testicle into the calf's body. It is about the size of a pencil and moves easily from side to side in its half of the scrotum. Pinch the cord to the outside edge of the scrotum between your thumb and forefinger. If right handed, use your left hand to hold the cord and your right to operate the Burdizzo.

4. Position the Burdizzo correctly for crushing. One jaw of the Burdizzo has projections at each end to keep the spermatic cord from slipping out of the Burdizzo. Place the jaw with the projections on the front side of the scrotum. Point the projections toward you.
5. Include only the part of the scrotum that contains the spermatic cord between the jaws of the Burdizzo. Do not crush more of the scrotum than necessary. The jaws should be placed just above (1-1.5 cm) the top of the testicle.
6. Close the Burdizzo, count out 10 seconds and check to be sure the spermatic cord has been held between the jaws of the Burdizzo. You can also rock the spermatic cord back and forth in the jaws.
7. Release the Burdizzo, move it to a new site 1 cm below your first site, and repeat steps four and five. Choose a site below the first crush to minimize acute pain from a second crush.
8. Repeat the procedure on the opposite side. Stagger the pinched areas on the left and right side of the scrotum. Do not pinch a part of the scrotum that lines up with a pinch on the opposite side. The crush lines must not overlap the centre-line of the scrotum (Figure 4).
9. Check calves four to six weeks later to be sure the testicles have shriveled. The testicles swell initially and then degenerate and shrink in size.

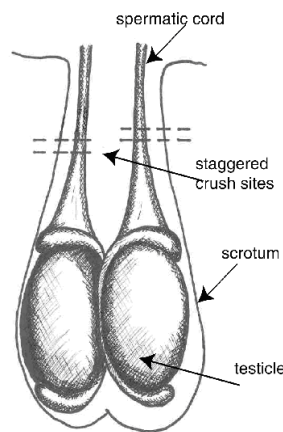


Figure 4. Burdizzo castration sites.

Pain:

- local anaesthesia plus a non-steroidal anti-inflammatory drug are needed to eliminate acute pain caused by Burdizzo castration
- acute pain caused by Burdizzo clamps is less than that caused by surgical, rubber-ring or latex-band castration

Advantages and Disadvantages:

- bloodless
- slow to perform and requires expertise

- unreliable when done incorrectly, leads to stags
- equipment becomes ineffective after long-term use and must be replaced
- less reduction in weight gain after castration compared to surgical or latex-band

Surgical Castration

Surgical castration is the most certain method of castration because the testicles are removed completely. It is best performed before or after fly season and when calves can be turned into a dry area after the surgery. Surgical castration can be performed on any age calf. It is easier to learn on calves with larger testicles. However, larger and older calves experience more stress and usually bleed more than younger calves.

Good restraint is essential to minimize the risk to calves and operators.

Instruments for surgical castration include the Newberry knife, scalpel (Figure 5) and emasculator.



Figure 5. Scalpel.

Technique

1. Wash and clean your hands and surgical equipment using an antiseptic solution. Position yourself at the side or rear of the calf and reach forward between the hind legs.
2. Make sure the scrotum is clean. You may use a mild surface disinfectant (such as iodine) to prepare the incision sites. This step is not useful if the hair is not shaved off or the area has not been scrubbed with soap several times.
3. Make an incision to open the skin of the scrotum using Method A or B.

Incision Method A

- Make the incisions on the outside of the lower half of each side of the scrotum (Figure 6).
- If you are right handed, use your left hand to force one testicle to the bottom outside of the scrotum. Once the testicle is in the proper site, hold it there and use a scalpel to make a generous incision over the testicle. The incision may extend into the testicle itself.

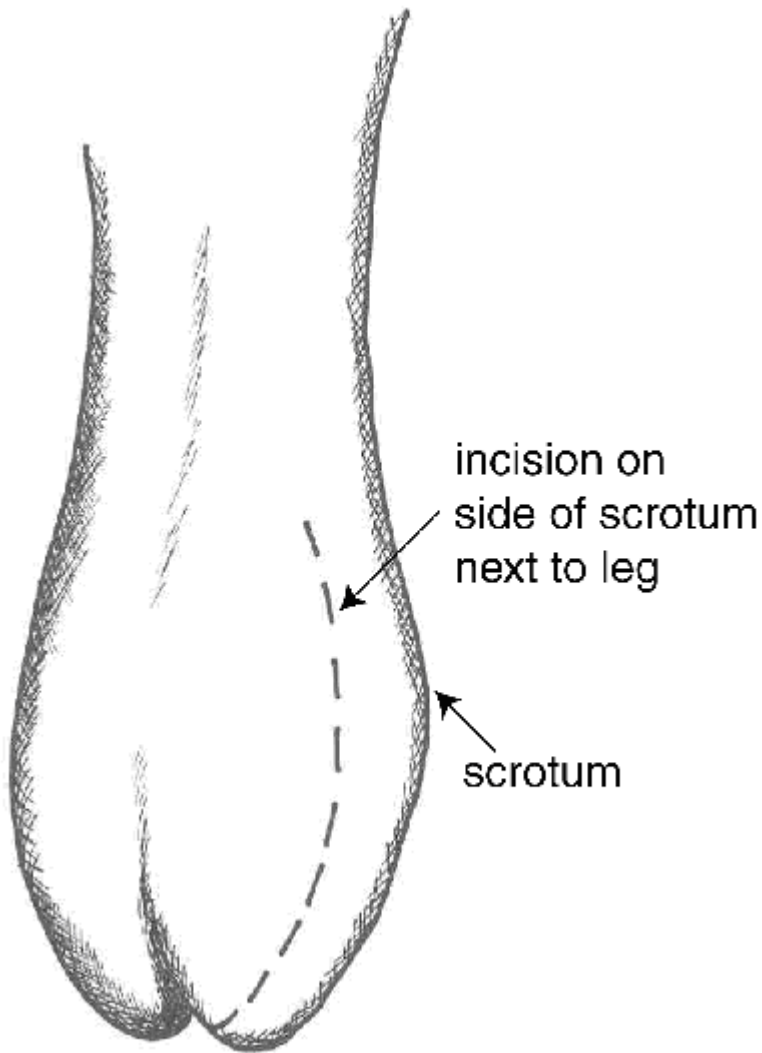


Figure 6. Incision method A.

Incision Method B

- Use one incision to remove the bottom third of the scrotum. To do this, first push the testicles up toward the body so the lower third of the scrotum is empty.
- Grasp the tip of the scrotum between your thumb and forefinger. Use a sharp scalpel to cut across the scrotum just above your thumb and finger. This cut will completely remove the tip of the scrotum and the testicles will fall down or can be pulled down by reaching up into the open scrotum (Figure 7).
- After making the incision, the remainder of the castration is similar.

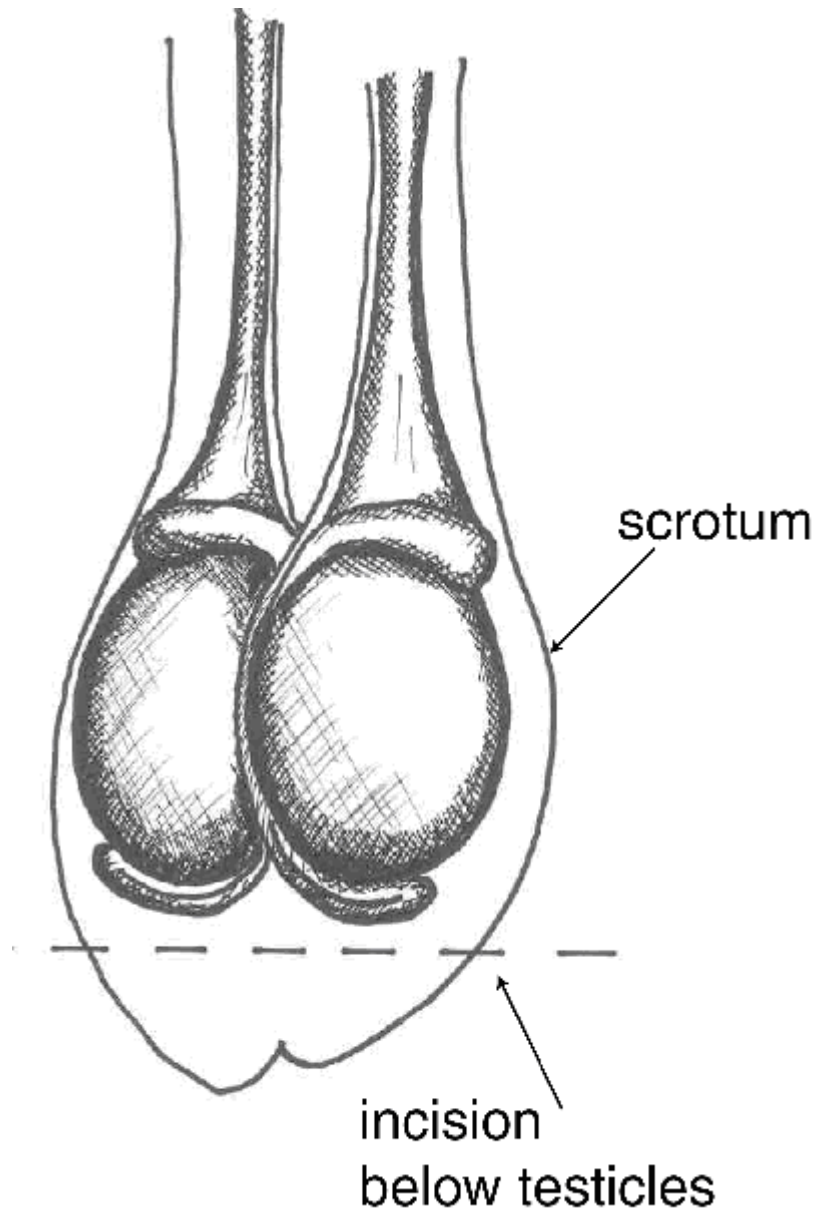


Figure 7. Incision method B.

4. Pull the testicle through the incision. It will be covered with a thin, but tough, white membrane. Separate this from the testicle by pulling it away near the tip of the testicle.
5. The remaining tough cord contains the artery, veins and spermatic cord.
6. In older calves, use an emasculator (Figure 8) to crush and cut both blood vessels and spermatic cord at the same time. An emasculator lessens the risk of bleeding. (The emasculator must be placed on the cord correctly in order to crush the cord properly).

7. In younger calves (<3 months), it is common to separate the blood vessels from the vas deferens. Shave through the vas with the scalpel. Gently pull the vessels until the strand breaks.
8. Repeat on the other side.



Figure 8. Emasculator.

There should not be any tissue hanging from the scrotum once the castration is complete.

If using incision Method B, the castration is complete. If using Method A, once both testicles have been removed, make an incision completely through the bottom half of the median septum to ensure good drainage.

Pain:

- local anaesthesia plus a non-steroidal anti-inflammatory drug eliminate acute pain caused by surgical castration
- acute pain caused by surgical castration is greater than that caused by Burdizzo clamps

Advantages and Disadvantages:

- not bloodless, bleeding is a risk
- sure castration because the testicles are removed
- more time to perform than banding
- risk of infections because of open wounds
- not recommended for castrating bull calves at a feedlot with wet, muddy conditions
- greater reduction in weight gain after castration compared to Burdizzo
- surgical wounds heal more quickly than those from rubber ring
- risk of injury to the surgeon

Chemical or Immunocastration

This type of castration, though not quite as effective as cutting or banding, is far more painless and less stressful on cattle than traditional methods. It is also less invasive, as all it involves is a needle, a syringe and a Chem-Cast(R) solution or a vaccine that targets hormones responsible for sexual characteristics and sperm production. This method

destroys the testicles and spermatic cords of bull calves weighing up to 150 lbs. It's not as effective on bulls over this weight.

Using the Immunocastration, however, is a vaccine that is being developed to target the hormones responsible for the sex characteristics and sperm production of the bull. So far, none of such vaccines have provided the possibility of long-term castration.

1. Prepare a needle and syringe for the operation.
2. Restrain the calf
3. Insert the needle from the top into the middle-third of one testicle, and inject the fluid according to the weight prescribed on the bottle.
4. Repeat for the other testicle.

Immunization as an Alternative to Castration

Researchers have shown immunization/vaccination techniques will suppress male hormone production, reduce testicular development and result in steer-like carcasses. Growth and carcass characteristics of the immunized animals are similar to steers. Researchers also have found that castration by immunization reduces aggressive behavior and is an effective alternative to surgical castration to manage bulls. However, there is no commercial product available for use. The need for repeated injections likely would discourage its adoption.

Aftercare:

- Provide a clean, dry environment for calves after castration
- Inspect the cattle closely for two weeks after castration. With latex bands, the scrotum should drop off within seven weeks after castration
- Look for swelling, signs of infection, tetanus and abnormal gait
 - The wound should be bathed with hot water, and antibiotics should be administered
 - The vet may open and drain the wound. You may have to make sure the wound gets cleaned out after the vet has done the initial clean-out, using warm water and an antiseptic
- Treat wounds as needed
- You may need to have a fly spray on hand if flies are going to become a problem

Complications:

As mentioned previously, tetanus is a worry in small ruminants and may be of concern in bulls that are castrated with the callicrate bander. Minimal complications— including seroma formation, swelling, and inflammation at the surgery site—are typical. These are usually self-limiting and resolve without further treatment. Other castration complications include infection and haemorrhage. With an open wound, any incisional infection or swelling can usually be handled by simply providing adequate ventral drainage and enlarging the incision bluntly. If appropriate technique is used, haemorrhage is rarely a

major problem. If persistent hemorrhage does occur, it may be necessary to pack the scrotum with a sterile towel, laparotomy pad, or gauze roll, with removal in 48 hours. When the sterile packing is removed, any retained blood clot should be gently expressed. If this is elected, antibiotics are appropriate since the packing material can serve as a foreign body in a closed space, thus making a localized infection more likely.