

Treatment of demodicosis in dogs: 2011 clinical practice guidelines

Ralf S. Mueller*, Emmanuel Bensignort, Lluís Ferrer‡, Birgit Holm§, Stephen Lemarie¶, Manon Paradis** and Michael A. Shipstone††

*Centre for Clinical Veterinary Medicine, Ludwig Maximilian University Munich, Veterinaerstraße 13, 80539 Munich, Germany

†Dermatology Referral Service, 75003 Paris, 35510 Rennes-Cesson and 44000 Nantes, France

‡Department of Animal Medicine and Surgery, Universitat Autònoma de Barcelona, 08193 Bellaterra, Spain

§The Blue Star Small Animal Hospital, Gjutjärnsgatan 4, SE-417 07 Gothenburg, Sweden

¶Southeast Veterinary Specialists, 3409 Division Street, Metairie, LA 70002, USA

**Department of Clinical Sciences, Faculté de Médecine Vétérinaire, University of Montreal, CP 5000, St-Hyacinthe, Québec, Canada J2S 7C6

††Dermatology for Animals, 263 Appleby Road, Stafford Heights, QLD 4053, Australia

Correspondence: Ralf S. Mueller, Centre for Clinical Veterinary Medicine, Ludwig Maximilian University Munich, Veterinaerstraße 13, 80539 Munich, Germany. E-mail: ralf.mueller@med.vetmed.uni-muenchen.de

Background and Objectives – These guidelines were written by an international group of specialists with the aim to provide veterinarians with current recommendations for the diagnosis and treatment of canine demodicosis.

Methods – Published studies of the various treatment options were reviewed and summarized. Where evidence in form of published studies was not available, expert consensus formed the base of the recommendations.

Results – Demodicosis can usually be diagnosed by deep skin scrapings or trichograms; in rare cases a skin biopsy may be needed for diagnosis.

Immune suppression due to endoparasitism or malnutrition in young dogs and endocrine diseases, neoplasia and chemotherapy in older dogs are considered predisposing factors and should be diagnosed and treated to optimize the therapeutic outcome. Dogs with disease severity requiring parasitocidal therapy should not be bred.

Secondary bacterial skin infections frequently complicate the disease and require topical and/or systemic antimicrobial therapy.

There is good evidence for the efficacy of weekly amitraz rinses and daily oral macrocyclic lactones such as milbemycin oxime, ivermectin and moxidectin for the treatment of canine demodicosis. Weekly application of topical moxidectin can be useful in dogs with milder forms of the disease. There is some evidence for the efficacy of weekly or twice weekly subcutaneous or oral doramectin. Systemic macrocyclic lactones may cause neurological adverse effects in sensitive dogs, thus a gradual increase to the final therapeutic dose may be prudent (particularly in herding breeds).

Treatment should be monitored with monthly skin scrapings and extended beyond clinical and microscopic cure to minimize recurrences.

Editor's Note – A brief review article by R. Mueller has been published: Evidence-based treatment of canine demodicosis, *Tierarztl Prax Ausg K Kleintiere Heimtiere* 2011; 39: 419–24. This is not considered to constitute duplication of the article published here in *Veterinary Dermatology*.

Accepted 24 October 2011

Sources of Funding: This study is self-funded.

Conflict of Interest: In the last 5 years, Ralf Mueller has obtained funding, lectured or consulted for Bayer Animal Health, Boehringer Ingelheim, Dechra Veterinary Products, Intervet, Merial, Novartis Animal Health, Pfizer Animal Health, Procter & Gamble, Royal Canin, Selectavet and Virbac. Emmanuel Bensignor has obtained funding for studies, lectured or consulted for the following companies selling products for demodicosis: Bayer Animal Health, Novartis Animal Health and Pfizer Animal Health. Lluís Ferrer has obtained funding, lectured or consulted for Novartis, Bayer Animal Health, Virbac, Merial, Intervet, Esteve Veterinaria and Elanco. Birgit Holm has obtained funding for studies, lectured or consulted for Bayer Animal Health and Novartis Animal Health. Manon Paradis has participated in a study funded by Bayer Animal Health. Michael Shipstone has received funding for studies and lectures from Pfizer Animal Health, Schering Plough and Virbac Australia.

Introduction

Objectives and explanation of this document

In humans, evidence-based medicine is not only an academic buzz word but has reached general practice. The Cochrane Collaboration (<http://www.cochrane.org/>) provides reviews and treatment guidelines for many common diseases and is available at no cost worldwide to anyone with Internet access. In veterinary dermatology, the first evidence-based medicine review was published in 2003 about treatments for canine atopic dermatitis.¹ This was followed with a Cochrane-type review² and practice guidelines publication for treatment of canine atopic dermatitis in 2010.³ These guidelines are available in a number of different languages as open access. Other topics in veterinary dermatology, such as fungal infec-

tions, leishmaniosis or otitis caused by *Pseudomonas*, have also been the subject of published evidence-based reviews.^{4–6}

Demodicosis is a common skin disease of the dog. Despite a number of studies evaluating pathogenesis and therapeutic options, treatment of canine demodicosis is still a matter of discussion in many conferences and continuing education courses. In October 2010, an international committee was founded to establish current evidence-based guidelines for treating canine demodicosis in practice. The committee consisted of members with long-standing interest in canine demodicosis as documented by several publications in the field, namely (in alphabetical order) Emmanuel Bensignor (France), Lluís Ferrer (Spain), Birgit Holm (Sweden), Stephen Lemarie (USA), Ralf S. Mueller (Germany), Manon Paradis (Canada) and Michael Shipstone (Australia). The aim of this committee was to develop best-practice guidelines for the treatment of canine demodicosis based on published evidence of efficacy. These guidelines are supported by the American College of Veterinary Dermatology, the Asian College of Veterinary Dermatology, the Asian Society of Veterinary Dermatology, the Canadian Society of Veterinary Dermatology, the Dermatology Chapter of the Australian College of Veterinary Scientists and the European Society of Veterinary Dermatology.

General comments

Throughout this article, recommendations for specific interventions were made based on the category of evidence (COE) described in Table 1 and on the highest evidence available at the time of writing. The categories have been modified from the human literature⁷ and a recent evidence review of treatment options for canine atopic dermatitis.² In general, recommendations of lower roman numeral numbers should be considered of greater value than those with higher grades.

For most of the recommendations in this article, the evidence was derived from results of a recent systematic review⁸ (COE I) or clinical trials (COE II). There are few randomized controlled studies published evaluating therapeutic options for canine demodicosis.^{9,10} To the authors' knowledge, there is not a single placebo-controlled clinical trial, and the rate of spontaneous remission of dogs with generalized demodicosis is not known. The use of recommended treatments will not always result in complete clinical and microscopic remission or even in a response acceptable to the owner. Likewise, insufficient evidence does not imply that a specific drug is not effective but rather that there are no published studies documenting efficacy or lack thereof.

Recommendations for a specific intervention did not take into consideration whether a product was available

in a specific country and whether it was licensed for use in dogs and, specifically, to treat canine demodicosis. Before implementing these guidelines into practice, veterinarians need to verify the legality of using the various veterinary pharmaceutical products and treatment protocols in their respective countries. Finally, a one-page summary is provided at the end of this article.

Pathogenesis of the disease

Demodex mites are considered to be a normal part of the cutaneous microfauna in the dog¹¹ and are transmitted from the bitch to the pups during the first days of life.¹² Puppies raised in isolation after caesarean section do not have any *Demodex* mites. It is assumed that immunosuppression or a defect in the skin immune system allows for mites to proliferate in hair follicles, resulting in clinical signs.¹² In addition to the most commonly encountered *Demodex* mite (*D. canis*), two other morphologically different types have been reported.^{13,14} One is the long-bodied *D. injai*, a mite commonly associated with greasy/oily skin and coat.^{15–18} The other is a short-bodied mite¹³ that has been reported in association with *D. canis*.^{19,20} However, more recent evidence has been presented that these different forms are all *D. canis*.²¹ Final determination will require genetic/molecular testing. Published data indicate similar efficacy of reported treatments regardless of the *Demodex* type (COE I).

In young animals, endoparasiticism,²² malnutrition and debilitation may lead to an immunocompromized state that favours mite proliferation and development of skin disease. In adult animals, chemotherapy, neoplasms, hypothyroidism or hyperadrenocorticism, for example, may suppress the immune system sufficiently to trigger proliferation of the mites.^{23–25} However, studies proving a cause–effect relationship between these factors and demodicosis are lacking. Many immunosuppressed dogs never develop demodicosis, and in many cases an underlying cause may not be found. In many publications, a juvenile-onset and an adult-onset form of the disease are differentiated.^{23–26} However, this differentiation may be difficult in individual cases. It is more important to identify and correct predisposing factors (such as endoparasitism or underlying diseases) independent of age to achieve the best possible outcome (COE IV).

Demodicosis in the dog is differentiated in a localized versus a generalized form. Localized demodicosis has a good prognosis, with the overwhelming majority of cases spontaneously resolving without miticidal treatment (COE V).²⁷ Topical antiseptic therapy may be recommended to prevent or treat a secondary bacterial skin infection (COE V).²⁷ Generalized demodicosis may be a severe and potentially life-threatening disease. The number of dogs with generalized demodicosis showing spontaneous cure is unknown at this time, although evidence for spontaneous remission in a subset of cases was recently presented.²⁸ The definition of localized versus generalized demodicosis has been a matter of debate. The reported lesion extent consistent with localized disease ranges from four lesions to 50% of the body surface.^{29,30} This committee considers demodicosis localized if there are no more than four lesions with a diameter of up to 2.5 cm (COE V).

Table 1. Different categories of evidence (COE)

COE I	Directly based on meta-analyses or systematic reviews
COE II	Directly based on several studies or case series
COE III	Directly based on at least one study or several case reports
COE IV	Directly based on one case report
COE V	Directly based on expert committee reports or opinions
COE VI	Directly based on laboratory studies

Clinical signs

Mild erythema, comedones and scaling may be the only lesions in mildly affected dogs. Partial or complete alopecia may develop. Multiple coalescing foci of alopecia and follicular papules characterize demodicosis of moderate severity. Follicular casts (scales adhering to the hair shafts) may be present. Follicular pustules and, in severe cases, furunculosis with scales, crusts, exudation and focal ulceration and draining tracts are observed with more advanced disease. Occasionally, nodules may be present.

Skin lesions often begin on the face and the forelegs and may progress to affect other body sites. Bilateral ceruminous otitis externa occasionally may be seen with demodicosis. Generalized demodicosis may be associated with lymphadenopathy, lethargy and fever. A secondary bacterial skin infection almost invariably accompanies generalized demodicosis. Pedal demodicosis may be associated with significant interdigital oedema and, particularly in larger dogs, may be distressingly painful.

Diagnosis of demodicosis

Deep skin scrapings

At this time, deep skin scrapings are the diagnostic test of choice in suspect cases.³¹ Curettes, spatula, sharp and dull scalpel blades can all be used to collect samples. Placing a drop of mineral oil on the sampling instrument and/or directly on the skin site can be helpful because debris adheres better to the instrument. Multiple scrapings (approximately 1 cm²) of affected skin are performed in the direction of the hair growth, and the skin should be squeezed during or between scrapings to extrude the mites from the deep follicles to the surface. Squeezing the skin has been shown to increase the number of mites found with the skin scrapings (COE III).³² The best yield is achieved with primary lesions, such as follicular papules and pustules. Ulcerated areas should not be scraped because mite yields may be low in such areas. The skin is scraped until capillary bleeding occurs, which indicates that the scraping has reached sufficient depth. In a long- or medium-haired dog, gently clipping the area to be scraped will minimize the loss of the scraped material into the surrounding hair. Debris is then transferred to a slide, mixed with mineral or paraffin oil and examined with a coverslip under the microscope at low-power magnification (×4 and ×10 lens).

Although *Demodex* mites are part of the normal microfauna, it is uncommon to find one mite even on several deep skin scrapings. If a mite is found, this should raise suspicion and additional skin scrapings should be performed. Finding more than one mite is strongly suggestive of clinical demodicosis (COE V).³¹ Different life stages (eggs, larvae, nymphs and adults) and their numbers should be recorded, compared from the same sites at each visit and used to evaluate response to treatment. Mites may be easier to find when the microscope condenser is lowered and the light decreased because this increases the contrast in the microscope field.

Trichograms

Trichograms have been reported as an alternative to deep skin scrapings^{32,33} and are particularly useful in areas that

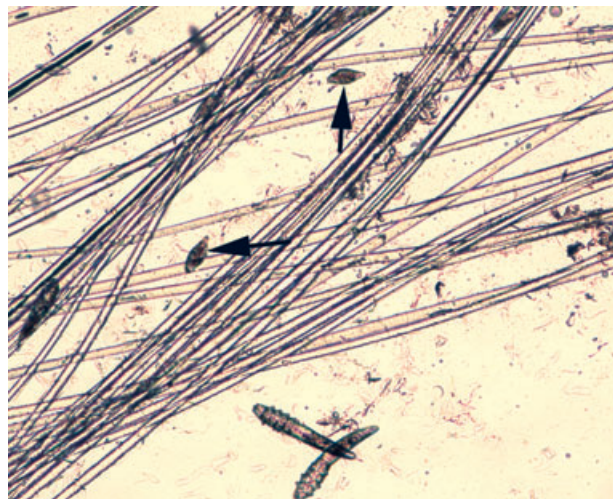


Figure 1. Photograph of a trichogram showing *Demodex* mites and eggs (arrows) in mineral oil (×100).

are difficult to scrape, such as periorcular and interdigital areas. Hairs from lesional skin are plucked with forceps in the direction of the hair growth and placed in a drop of mineral or paraffin oil on a slide (Figure 1). The use of a coverslip allows more thorough and rapid inspection of the specimen. To increase the chance of a positive trichogram, a large number of hairs (50–100) should be plucked. When performed properly, trichograms have a high diagnostic yield. However, negative trichograms should be followed by deep skin scrapings before ruling out demodicosis (COE III). Positive trichograms in healthy dogs are rare.³⁴

Skin biopsy

In some rare cases, skin scrapings and trichograms may be negative, and skin biopsies may be needed to detect the *Demodex* mites in the hair follicles or in foreign body granulomas in furunculosis. This may be more likely in certain body locations, such as the paws, and certain dog breeds, such as shar-peis.

Other methods of mite detection

Direct examination of the exudate from pustules or draining tracts may reveal mites in some dogs. Specimens can be collected by squeezing the exudate onto a glass slide and visualized by adding mineral oil or paraffin oil and a coverslip. In some cases where mites are very abundant, acetate tape preparations may also reveal mites. If affected dogs have lymphadenopathy, it is not uncommon to find mites on fine-needle aspirates. These methods cannot be used to rule out the presence of an infestation.

Identification of bacterial infections (using clinical signs, skin cytology and culture)

Frequently, generalized demodicosis is associated with secondary bacterial skin infections. In severe cases with furunculosis, bacterial septicaemia is possible. When clinical signs of a possible bacterial skin infection (e.g. papules, pustules) are present, an impression smear should be obtained, stained and evaluated for an increased num-

ber and/or intracellular location of bacterial organisms. Most commonly, *Staphylococcus pseudintermedius* will be present,⁸ but in some dogs, particularly those with furunculosis, Gram-negative rods, such as *Escherichia coli* or *Pseudomonas aeruginosa*, may predominate.

Treatment of canine demodicosis

Treatment of canine generalized demodicosis is multimodal. In addition to effective acaricidal therapy, treatment of concurrent bacterial skin infection, internal parasitism and underlying systemic disease must be undertaken to maximize the potential for successful treatment (COE V).

Treatment of secondary bacterial skin infection

Cytology is essential in the evaluation of a dog with demodicosis (see identification of bacterial infections above). When an infection is present, it should be treated based on the standard of care in each country. It is beyond the scope of these guidelines to detail recommendations for antimicrobial therapy. Ideally, a bacterial culture should be performed to determine the choice of antibiotic. Culture and susceptibility testing are ideal in dogs with rod-shaped bacteria present on cytology, in cases with apparent bacterial resistance or in very severe, potentially life-threatening infection (COE V). If a culture is not possible, cytological determination of the bacterial type (rods or cocci) is essential prior to empirical antibiotic therapy, because many antibiotics empirically suited for Gram-positive coccal infections are ineffective for Gram-negative rods.

Appropriate oral antibiotic therapy and concurrent topical antimicrobial therapy (whole-body soaks or shampoos) are recommended for all dogs with generalized demodicosis and secondary bacterial skin infection (COE V). In addition to antimicrobial benefits, topical therapy contributes to the overall wellbeing of the dog by removing crusts and debris that may contain mites, exudate and inflammatory mediators. Benzoyl peroxide (2–3%) and chlorhexidine-based shampoos (3–4%) are commonly recommended for dogs with demodicosis. They have a prolonged antibacterial activity on skin.³⁵ Benzoyl peroxide is degreasing, thus drying, and may be irritant, so it may be prudent to follow up with a moisturizer to prevent drying of the skin.³⁶ The frequency of topical therapy depends on the dog, owner and concurrent miticidal therapy, but weekly bathing is most commonly recommended (COE V). Antimicrobial therapy should be continued for 1–2 weeks beyond clinical and microscopic resolution of the bacterial skin infection.

Amitraz

Amitraz as a rinse has been approved for the treatment of canine generalized demodicosis in many countries for decades. It has been shown to be an effective treatment option in many studies (COE I).⁸ The recommended concentration varies from 0.025 to 0.06%, with a frequency of once weekly to every 2 weeks.⁸ Clinical efficacy increases with increasing concentration and shorter treatment intervals (COE II).^{37,38} Intensive protocols with daily rinsing of alternating body halves at a concentration of 0.125%³⁹ or weekly treatment with an amitraz concentra-

tion of 1.25%³⁷ have been reported in dogs not responding to conventional therapies. In the latter report, dogs were treated once with atipamezole (0.1 mg/kg intramuscularly) followed by oral yohimbine (0.1 mg/kg) once daily for 3 days to minimize systemic adverse effects.³⁷ These intensive protocols should be reserved for dogs failing routine treatment.

When using amitraz rinses, it is essential to clip the hair coat in dogs with medium to long hair coat (COE V).⁴⁰ This needs to be repeated as needed during the treatment course. The rinse should be applied carefully with a sponge and soaking the skin, and allowed to air dry without rinsing. Dogs should not be allowed to get wet between rinses, to avoid washing off the amitraz. Treatment of pedal demodicosis with amitraz rinses may be problematic in wet environments because it is difficult to maintain the amitraz on the pedal skin in these circumstances. Daily treatment of the paws²⁷ or using other treatment modalities may be needed (COE V). Adverse effects of amitraz reported in various studies were depression, sleepiness, ataxia, polyphagia, polydipsia, vomiting and diarrhoea.⁸ Amitraz anecdotally has caused headaches and asthma in owners, thus it is commonly recommended that dogs should be washed in a well-ventilated area.^{8,27,41}

Based on published studies, amitraz rinses seem to be less efficacious in dogs with adult-onset demodicosis.⁸ Weekly treatment is recommended (COE I). As approved concentrations and treatment interval vary from country to country, veterinarians need to choose the treatment protocol approved in their location based on their country's regulatory agency guidelines.

More recently, a spot-on preparation with 15% amitraz and 15% metaflumizone has been used in some countries as a monthly treatment for canine demodicosis. Pilot studies showed promising results with administration monthly⁴² and every 2 weeks.^{42,43} However, pemphigus foliaceus-like drug reactions have been reported after the use of the spot-on, and some dogs required long-term immunosuppressive therapy for the treatment of this disease even after the use of spot-on was discontinued.⁴⁴ The manufacturer indicated that the production of this spot-on is discontinued in North America at the time of writing but apparently still sold in other parts of the world. Based on the reported cases of drug-induced pemphigus foliaceus,⁴⁴ this spot-on preparation should not be routinely used for the treatment of canine demodicosis, but should be reserved for cases not responding to other treatment options.

Macrocyclic lactones

Milbemycin oxime

Milbemycin oxime is licensed for the treatment of canine demodicosis in some countries at a dose of 0.5–2 mg/kg daily orally (p.o.). In studies from the USA and Australia, a clearly higher success rate was seen with a higher dose of 1–2 compared with 0.5–1 mg/kg.^{25,26,41} This is in contrast to a Swedish study, where good results were achieved with the low-dose protocol,⁴⁵ possibly because most dogs in this study were diagnosed early in the disease and had not previously been treated with other mite-

cides. In contrast, the other studies were conducted in referral practices with potentially more chronically and severely affected patients. Alternatively, a different genetic base of the dogs or different susceptibility of the mites to milbemycin oxime may have influenced the results. The success rate of milbemycin oxime was shown to be much lower in dogs with adult-onset demodicosis (COE I).^{25,45} Milbemycin oxime has been administered to collie dogs at a dose of 2.5 mg/kg daily for 10 days without adverse effects,⁴⁶ and there seems to be a high safety margin with this drug.⁸ However, dogs homozygous for the *ABCB1-Δ1* (MDR-1) mutation developed ataxia with milbemycin oxime at a dose of approximately 1.5 mg/kg daily, but tolerated the drug at 0.6 mg/kg/day.⁴⁷

At this time, milbemycin oxime is recommended for the treatment of canine generalized demodicosis at a dose of 1–2 mg/kg p.o. daily. A lower efficacy is seen with adult-onset demodicosis (COE I). In herding breed dogs, it is advised to evaluate the *ABCB1-Δ1* (MDR-1) genotype and to use lower doses or increase the dose gradually in dogs homozygous for the *ABCB1-Δ1* (MDR-1) mutation (COE V).

Ivermectin

Ivermectin is not licensed for use in canine demodicosis. It has been used as weekly injection at a dose of 0.4 mg/kg subcutaneously (s.c.) with variable and inconsistent results.⁴⁸ Thus, injectable weekly treatment cannot be recommended at this time for the treatment of canine generalized demodicosis (COE III). However, there are a number of studies evaluating daily oral ivermectin at a concentration of 0.3–0.6 mg/kg with similar outcome measures and treatment success.^{29,49–53} An evidence-based review concluded that oral ivermectin at a dose of 0.3–0.6 mg/kg daily can be recommended as therapy for canine generalized demodicosis (COE I).⁸ Ivermectin can cause severe neurological adverse effects, such as lethargy, tremors, mydriasis and death in sensitive dogs (COE I). Anecdotally, blindness has also been seen. Collie dogs and other herding breeds are most commonly affected, but other breeds have also been reported.⁵⁴ Thus, a gradual dose increase from 0.05 mg/kg on day 1 to 0.1 mg/kg on day 2, 0.15 mg/kg on day 3, 0.2 mg/kg on day 4 and 0.3 mg/kg on day 5 is recommended in any dog treated with ivermectin (COE III).⁵⁴ When higher daily doses are used then a further increase by 0.1 mg/kg/day is recommended. Other P-glycoprotein inhibitors, such as ketoconazole or ciclosporin, if given concurrently, increase the likelihood of adverse effects (COE III).^{55,56}

More recently, an *ABCB1-Δ1* (MDR-1) mutation considered responsible for the acute toxicity in collie dogs and several other herding breeds has been identified.^{57–59} Testing for this defect is possible. However, in a recent study evaluating 28 'nonsensitive' breed dogs with neurological adverse effects to daily ivermectin after 4 days to 5 weeks of therapy,⁶⁰ 27 dogs did not show an alteration of the *ABCB1-Δ1* (MDR-1) gene, thus other mechanisms of toxicity must exist. Based on published studies, ivermectin at 0.3–0.6 mg/kg p.o. daily is an effective therapy for canine demodicosis (COE I), but the dose needs to be

gradually increased (COE III) and dogs monitored for adverse effects. If such adverse effects occur, ivermectin administration should be discontinued. In some cases, it may be indicated to attempt administering a lower dose of ivermectin; if this is successful and clinical signs of toxicity resolve, therapy may be continued at the lower dose. This approach is not recommended in dogs with acute toxicity within days of beginning treatment, but is often effective in dogs developing adverse effects after some weeks of therapy (COE V). Dogs of breeds known to be at risk should be tested for the *ABCB1-Δ1* gene mutation (where this is possible) or receive alternative treatments.

Moxidectin

Moxidectin has been used in a number of studies at doses of 0.2–0.5 mg/kg/day p.o. with comparable success to ivermectin.^{53,61–63} Adverse effects are similar to those of ivermectin,⁸ and a gradual dose increase similar to that described for ivermectin was used in two of the studies.^{62,63} However, adverse effects are more common. In one study, treatment was discontinued due to lethargy, vomiting and ataxia in three of 22 dogs. In one dog, adverse effects were noted at a dose of 0.28 mg/kg and in the other two dogs it occurred at 0.4 mg/kg. In another study, adverse effects were seen in 12 of 35 dogs treated with moxidectin at 0.5 mg/kg every 72 h. The most common adverse effects were vomiting and inappetence, but these were not severe enough to warrant discontinuation of therapy.

Based on the published evidence, moxidectin at 0.2–0.5 mg/kg p.o. daily can be recommended as an effective therapy for canine demodicosis (COE I); an initial gradual dose increase and careful monitoring are recommended, similar to oral ivermectin.

Moxidectin has also become available as a 2.5% spot-on formulation (in combination with 10% imidacloprid). Initial studies evaluating the spot-on as monthly treatment for generalized demodicosis were encouraging.⁶⁴ However, clinical use did not corroborate the findings, and subsequent studies revealed that the spot-on was more efficacious in juvenile dogs with milder forms of the disease³⁰ and that weekly therapy showed better results than twice monthly or monthly administration.^{9,65} Based on these results, the label of this product was changed to recommend weekly administration in many countries where it has been approved for the treatment of canine demodicosis. Currently, the spot-on containing 2.5% moxidectin and 10% imidacloprid can be recommended as weekly treatment for dogs with juvenile-onset and mild forms of the disease (COE II). If significant improvement is not seen within the first few weeks, other therapy may be indicated.

Doramectin

Doramectin is also a macrocyclic lactone that has been reported as a successful treatment for canine demodicosis.^{66,67} In one study, it was administered at 0.6 mg/kg s.c. weekly;⁶⁶ in the second study, it was administered at the same dose p.o. once weekly.⁶⁷ In the latter study, two dogs that did not improve clinically responded to 0.6 mg/kg p.o. twice weekly, but one of them, a golden retriever, developed ataxia and subsequently was treated

twice weekly with 0.3 mg/kg doramectin. The recurrence rate was higher in dogs with adult-onset disease (as seen with amitraz and milbemycin oxime; COE III). Based on these two studies, there is evidence that doramectin at a dose of 0.6 mg/kg p.o. or s.c. weekly may be used for the treatment of demodicosis (COE III).

The question of whether more frequent administration increases the success rate without unacceptable adverse effects has to be evaluated by further, preferably by randomized blinded trials. The effect of 1 mg/kg doramectin on *Ancylostoma caninum* and *Toxocara canis* has been evaluated in pregnant beagle bitches, and no adverse effects were seen.^{68,69} Likewise, beagle dogs were treated with 0.4 mg/kg s.c. doramectin for *Spirocerca lupi* with no adverse effects.⁷⁰ However, subcutaneous doramectin at 0.2 and 0.7 mg/kg, respectively, caused severe neurological signs in a collie dog⁷¹ and two white Swiss German shepherd dogs with an MDR-1 mutation⁷² approximately 24 h after a single administration; thus it is recommended to gradually increase the doramectin dose to identify drug-sensitive dogs in a similar manner to the recommendations for ivermectin and moxidectin.

Other treatment options

In addition to various medical treatments, it seems prudent, based on published information, to recommend good control of endoparasites, a balanced, high-quality diet and avoidance of immunosuppressive treatments if at all possible (COE V).

There are a number of other reports evaluating various treatments, most of which are summarized in a published review.⁸ A recently published study showed that treatment with selamectin at a dose of 24–48 mg/kg p.o. once weekly or twice monthly had a low success rate in canine generalized demodicosis (COE III).¹⁰

There is insufficient evidence to recommend treatment of canine demodicosis with amitraz collars, closantel, deltamethrin, vitamin E, herbal and homeopathic preparations, muramyl dipeptide and phoxime.⁸ There is evidence against the use of pour-on or injectable weekly ivermectin, lufenuron, ronnel, oral selamectin and levamisole (COE III).^{8,10}

Treatment duration, monitoring and prognosis

It is not sufficient to rely on clinical appearance as the end-point of treatment. Clinically normal dogs may still harbour mites on skin scrapings. Microscopic cure, defined as multiple negative skin scrapings, in addition to resolution of clinical signs is needed to determine the therapeutic end-point. In general, it is recommended to scrape repeatedly the three to five most severely affected areas and any new lesions monthly until all three to five scrapings are negative. As only small areas are scraped, which may not be representative of the dog as a whole, it is recommended to continue treatment for 1 month after the second negative monthly set of skin scrapings. In dogs that responded very slowly to therapy, extend treatment even further (COE V).

The prognosis for canine demodicosis is good, with the majority of cases achieving long-term remission.⁸ However, dogs with an incurable or poorly controlled underlying disease may never be cured and may require long-term

therapy (e.g. monthly amitraz rinses or weekly ivermectin administration). Development of *Demodex* mite resistance against miticides has not been documented at this point to the authors' knowledge. Whether low-dose long-term glucocorticoid therapy for allergic disease is sufficient immunosuppression to trigger generalized demodicosis has not been evaluated to the authors' knowledge. The current recommendation is to avoid long-term glucocorticoid therapy in dogs with a history of demodicosis (COE V).

Based on published studies, a recurrence of the disease in the first 1–2 years after cessation of therapy does occur in a small number of dogs.⁸ The majority of these cases achieve remission with a repeat of the same treatment regimen or with another type of therapy.⁸ In more recent studies, a follow-up period of 12 months is recommended to monitor for relapse. It is recommended to monitor dogs closely for recurrence of clinical disease during the first 12 months after treatment has been discontinued.

How should dogs with adult-onset demodicosis be evaluated for underlying diseases?

Adult-onset demodicosis is defined as the development of demodicosis in an adult dog with no known prior history of the disease. In adult animals, immunosuppressive therapy and diseases such as neoplasms, hypothyroidism or hyperadrenocorticism have been reported to be associated with generalized demodicosis.^{23–25} Evaluation for an underlying disease may include, but not be limited to, the following tests: a complete blood count, biochemistry panel and urinalysis, lymph node aspirate, radiographs of the chest and ultrasound of the abdomen.

Hyperadrenocorticism and hypothyroidism should be investigated; if there are no other supporting signs of hormonal diseases, urine cortisol creatinine ratio may be used to rule out hyperadrenocorticism (COE V). Evaluation of thyroid hormone concentrations can be difficult. Chronic stress due to generalized demodicosis and secondary deep bacterial skin infection may influence results of these tests. Thyroxine concentrations may be decreased due to euthyroid sick syndrome, and the urine cortisol creatinine ratio may be increased. Depending on the individual case situation, veterinarians need to consider postponing diagnostic tests for hormonal disease until the bacterial skin infection is treated and the demodicosis is improved or in remission. If owners of dogs showing no other clinical signs of disease refuse further diagnostic evaluation, close monitoring of the dog until development of further clinical clues should be recommended (COE V). If systemic signs point to a particular disease, that disease should be confirmed and treated, as evidence shows that successful treatment of an underlying cause may contribute to remission of the demodicosis (COE IV).¹⁵

Should dogs with demodicosis be allowed to breed?

Demodicosis in young dogs is most likely to be based on one or more genetic traits, as supported by strong breed predispositions⁷³ and the fact that selective breeding has decreased the incidence of demodicosis in breeding kennels.²⁷ To prevent an increase in prevalence of canine demodicosis, it is recommended not to breed from any dog with generalized demodicosis^{27,74} and to neuter

affected animals. This is especially important in the bitch, as oestrus cycles may trigger recurrence of clinical disease (COE III),⁷⁵ providing a further argument for neutering these animals.

Almost 30 years ago, the American Academy of Veterinary Dermatology recommended that 'the AAVD urges veterinarians to accept for therapy only those generalized demodicosis patients who have been or will be neutered'.⁷⁶ However, the definition of generalized demodicosis is subjective and thus this recommendation may lead to different outcomes with different breeders and veterinarians. The reported lesion extent consistent with localized disease ranges from four lesions to 50% of the body surface.^{29,30} There is little information on the measured lesional area that is considered localized and whether the size of a lesion considered localized is influenced by the size of the dog. It is also not known whether an area with papules, pustules, exudation, crusting and ulcers is comparable to an area characterized by alopecia and comedones only. Thus, the authors consider that differentiation is only of limited help to the practitioner. In addition, it is unclear whether treatment of localized demodicosis will prevent the disease from becoming generalized, or if a dog predisposed to generalized demodicosis would develop it even if topical treatment were used initially on the first localized lesions. Studies to answer these questions are urgently needed. The main reasons for differentiating the two forms are the prognosis and the decision about neutering the dog to prevent breeding.

Currently, the consensus of this committee is as follows. As there is no scientific basis for a clear and consistent differentiation between localized and generalized demodicosis, ideally all dogs with demodicosis should be eliminated from the breeding pool. As this is not a realistic outlook for many breeds, breeding recommendations should be based on the need for specifically treating the dog for demodicosis. In a dog with clinical signs of demodicosis limited to one or few areas of the body and not affecting the general wellbeing of the dog, it is acceptable to use antimicrobial shampoos only and refrain from mite-specific therapies. However, if the disease continues to progress such that specific miticidal treatment is required, neutering the animal to prevent breeding is strongly recommended (COE V).

Problem no. 1: treatment of localized demodicosis

Case scenario no. 1

A 6-month-old female West Highland white terrier was presented with three small areas, approximately 5 cm², of alopecia (Figure 2). Scrapings show numerous adult *Demodex* mites, larvae and eggs.

Scenario 1a: the alopecic areas are slightly scaly with a few comedones.

Scenario 1b: papules, pustules and crusts are prominent in the alopecic areas.

Treatment options for scenario 1a:

- 1 This dog would qualify for localized demodicosis. Thus, initially simple monitoring of the dog for fur-

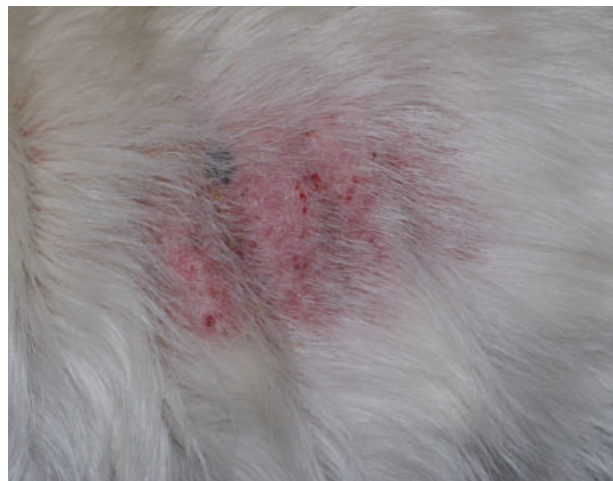

Figure 2. Photograph of the trunk of a 6-month-old West Highland white terrier with localized demodicosis. Note the focal alopecia, erythema, papules and small ulcers and crusts.

ther progression to generalized disease or spontaneous remission is the recommended option.

- 2 If the owner desires therapy, topical antiseptic shampoos (e.g. benzoyl peroxide or chlorhexidine) are recommended once to twice weekly (COE V). Benzoyl peroxide is a degreasing and thus drying shampoo and may need to be followed up with a moisturizer to prevent dry, scaly and pruritic skin.

Treatment options for scenario 1b:

- 1 This dog would still qualify for localized demodicosis. Thus, initially simple monitoring of the dog for further progression to generalized disease or spontaneous remission is a possible option. However, the papules and crusts indicate a possible bacterial secondary infection, and an impression smear is indicated to look for the presence of bacteria. The ideal method is an aspiration of an intact pustule. Alternatively, an impression smear can be obtained after rupturing a pustule. Topical antiseptic shampoos (e.g. containing benzoyl peroxide or chlorhexidine) should be recommended once to twice weekly (COE V).
- 2 If, in addition to the presence of inflammatory cells, there is a large number of intra- and/or extracellular bacteria, an oral antibiotic may be required. Oral antibiotic therapy should ideally be selected based on bacterial culture and susceptibility, particularly if the dog has been previously treated with antibiotics. Alternatively, topical antiseptic therapy can be used as frequently as daily or every other day.

Problem no. 2: treatment of generalized demodicosis

Case scenario no. 2

A 6-month-old male pug is presented with generalized hypotrichosis, scaling and multifocal areas of alopecia and erythema.

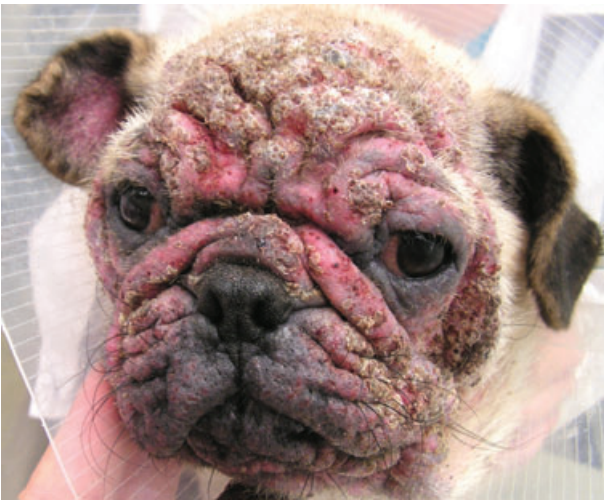

Figure 3. Photograph of the face of a 6-month-old pug with demodicosis. Severe alopecia, erythema, erosions, ulcers and crusts can be seen.

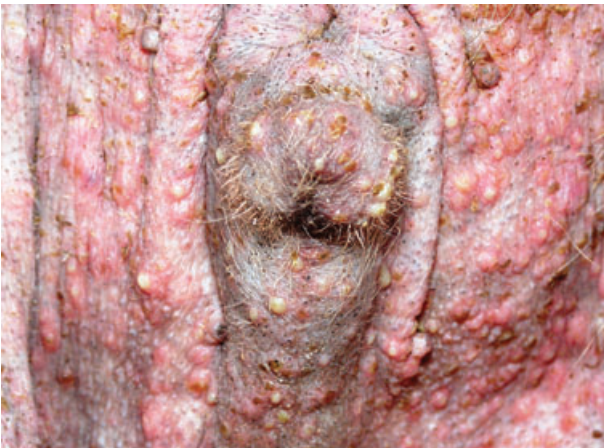

Figure 4. Photograph of the preputial area of the pug from Figure 3. Alopecia, erythema, papules, pustules and crusts are present.

Scenario 2a: the alopecic areas are scaly and erythematous with a few comedones.

Scenario 2b: papules, pustules, crusts and copious exudation are prominent in the alopecic areas. An exudative pododermatitis is also present. The dog shows lethargy and an increased body temperature (Figures 3 and 4).

Treatment options for scenario 2a:

- 1 Cytology and culture of skin lesions should determine whether oral antibiotic therapy is needed. Even without evidence of an active infection, topical antibacterial therapy is indicated to minimize the chance of a secondary bacterial skin infection developing.
- 2 Miticidal therapy is indicated. Topical moxidectin weekly is a convenient and safe treatment option that can be recommended for this dog (COE II). Other alternatives are amitraz rinses weekly or every 2 weeks, oral daily milbemycin oxime, iver-

mectin or moxidectin (initially in gradually increasing doses; COE I) or weekly doramectin (COE III). Treatment should be chosen based on the legal conditions in the respective countries.

- 3 Monthly skin scrapings should be performed and treatment changed if either clinical signs and/or mite numbers on skin scrapings have not improved from the last visit. Once clinical and, most importantly, microscopic remission have been achieved, treatment should ideally be continued for a further 4–8 weeks (COE V).
- 4 Close monitoring of dogs for recurrence is recommended, particularly during the first 12 months of remission.
- 5 Long-term glucocorticoid therapy or other immunosuppression should be avoided, if at all possible (COE V).

Treatment options for scenario 2b:

- 1 The situation may require administration of empirical antibiotic therapy pending culture and susceptibility results. Cytology should determine which kind of antibacterial agent has the highest empirical value. Ideally, an aspirate should be taken from an intact pustule for culture and sensitivity testing before empirical antibiotic therapy is begun, and a complete blood count and biochemistry panel should be obtained. Hospitalization of the dog and administration of intravenous fluid and antibiotics may be considered based on the clinical condition of the dog and initial laboratory investigation. Once culture results are known, antibiotic therapy may have to be adjusted. Antimicrobial therapy should be continued for 1–2 weeks after clinical and microscopic resolution of the bacterial skin infection (COE V).
- 2 Topical antibacterial therapy is indicated to remove bacteria, crusts and inflammatory mediators from the skin surface (COE V). In some severely affected dogs, it may be necessary to delay topical therapy until the dog's systemic signs have improved and the stress of bathing is more easily tolerated.
- 3 Miticidal therapy is indicated. Topical amitraz rinses, milbemycin oxime at high doses, oral ivermectin or moxidectin (in gradually increasing doses; COE I) or weekly doramectin (COE III) may all be considered based on the legal situation.
- 4 Initially, the dog ideally should be evaluated weekly until lethargy and increased body temperature have resolved. Treatment changes should be considered if neither clinical signs nor mite numbers on skin scrapings have changed after a month. Thereafter, monthly skin scrapings are indicated. Once clinical and microscopic remission have been achieved, treatment should ideally be continued for a further 4–8 weeks (COE V).
- 5 Close monitoring of dogs for recurrence is recommended, particularly during the first 12 months of remission.
- 6 Long-term glucocorticoid therapy or other immunosuppression should be avoided, if at all possible (COE V).

Acknowledgements

The authors would like to thank the involved presidents and board members of the many professional organizations for their time to review these guidelines and their support. They are grateful for Kinga Gortel's helpful suggestions regarding the manuscript.

Supporting Information

Additional Supporting Information may be found in the online version of this article:

Folder S1. Translations of the paper 'Treatment of demodicosis in dogs: 2011 clinical practice guidelines'.

Please note: Wiley-Blackwell are not responsible for the content or functionality of any supporting materials supplied by the authors. Any queries (other than missing material) should be directed to the corresponding author for the article.

References

- Olivry T, Mueller RS. Evidence-based veterinary dermatology: a systematic review of the pharmacotherapy of canine atopic dermatitis. *Veterinary Dermatology* 2003; 14: 121–146.
- Olivry T, Foster AP, Mueller RS *et al.* Interventions for atopic dermatitis in dogs: a systematic review of randomized controlled trials. *Veterinary Dermatology* 2010; 21: 4–22.
- Olivry T, DeBoer DJ, Favrot C *et al.* Treatment of canine atopic dermatitis: 2010 clinical practice guidelines from the International Task Force on Canine Atopic Dermatitis. *Veterinary Dermatology* 2010; 21: 233–248.
- Moriello KA. Treatment of dermatophytosis in dogs and cats: review of published studies. *Veterinary Dermatology* 2004; 15: 99–107.
- Nuttall T, Cole LK. Evidence-based veterinary dermatology: a systematic review of interventions for treatment of *Pseudomonas* otitis in dogs. *Veterinary Dermatology* 2007; 18: 69–77.
- Noli C, Auxilia ST. Treatment of canine Old World visceral leishmaniasis: a systematic review. *Veterinary Dermatology* 2005; 16: 213–232.
- Leung DY, Nicklas RA, Li JT *et al.* Disease management of atopic dermatitis: an updated practice parameter. Joint Task Force on Practice Parameters. *Annals of Allergy, Asthma & Immunology* 2004; 93: S1–S21.
- Mueller RS. Treatment protocols for demodicosis: an evidence-based review. *Veterinary Dermatology* 2004; 15: 75–89.
- Paterson TE, Halliwell RE, Fields PJ *et al.* Treatment of canine-generalized demodicosis: a blind, randomized clinical trial comparing the efficacy of Advocate® (Bayer Animal Health) with ivermectin. *Veterinary Dermatology* 2009; 20: 447–455.
- Schnabl B, Bettenay S, Glos N *et al.* Oral selamectin in the treatment of canine generalised demodicosis. *Veterinary Record* 2010; 166: 710–714.
- Hempf Olschewski C. *Hat Jeder Hautgesunde Hund Demodexmilben? Histologische Untersuchungen von Hautproben.* Berlin: Freie Universität, 1988; 141.
- Greve JH, Gaafar SM. Natural transmission of *Demodex canis* in dogs. *Journal of the American Veterinary Medical Association* 1966; 148: 1043–1045.
- Chesney CJ. Short form of *Demodex* species mite in the dog: occurrence and measurements. *Journal of Small Animal Practice* 1999; 40: 58–61.
- Desch CE, Hillier A. *Demodex injai*: a new species of hair follicle mite (Acari: Demodecidae) from the domestic dog (Canidae). *Journal of Medical Entomology* 2003; 40: 146–149.
- Hillier A, Desch CE. Large-bodied *Demodex* mite infestation in 4 dogs. *Journal of the American Veterinary Medical Association* 2002; 220: 623–627, 613.
- Mueller RS, Bettenay SV. An unusual presentation of generalised demodicosis caused by a long-bodied demodex mite in a Lakeland Terrier. *Australian Veterinary Practitioner* 1999; 29: 128–131.
- Ordeix L, Bardagi M, Scarampella F *et al.* *Demodex injai* infestation and dorsal greasy skin and hair in eight wirehaired fox terrier dogs. *Veterinary Dermatology* 2009; 20: 267–272.
- Robson DC, Burton GG, Bassett R *et al.* Eight cases of demodicosis caused by a long-bodied *Demodex* species (1997–2002). *Australian Veterinary Practice* 2003; 33: 64–72.
- Chen C. A short-tailed demodectic mite and *Demodex canis* infestation in a Chihuahua dog. *Veterinary Dermatology* 1995; 6: 227–229.
- Saridomichelakis M, Koutinas A, Papadogiannakis E *et al.* Adult-onset demodicosis in two dogs due to *Demodex canis* and a short-tailed demodectic mite. *Journal of Small Animal Practice* 1999; 40: 529–532.
- Bourdeau P. Variation in size in *Demodex canis*: from the longest to the shortest forms. *Veterinary Dermatology* 2010; 21: 213 (Abstract).
- Plant JD, Lund EM, Yang M. A case-control study of the risk factors for canine juvenile-onset generalized demodicosis in the USA. *Veterinary Dermatology* 2011; 22: 95–99.
- Duclos DD, Jeffers JG, Shanley KJ. Prognosis for treatment of adult-onset demodicosis in dogs: 34 cases (1979–1990). *Journal of the American Veterinary Medical Association* 1994; 204: 616–619.
- Lemarie S, Hosgood G, Foil CS. A retrospective study of juvenile- and adult-onset generalized demodicosis in dogs (1986–1991). *Veterinary Dermatology* 1996; 7: 3–10.
- Miller WH Jr, Scott DW, Wellington JR *et al.* Clinical efficacy of milbemycin oxime in the treatment of generalized demodicosis in adult dogs. *Journal of the American Veterinary Medical Association* 1993; 203: 1426–1429.
- Garfield RA, Lloyd R. The use of oral milbemycin oxime (Interceptor) in the treatment of chronic generalized canine demodicosis. *Veterinary Dermatology* 1992; 3: 231–235.
- Scott DW, Miller WH Jr, Griffin CE. *Canine demodicosis.* Muller & Kirk's *Small Animal Dermatology*. Philadelphia, W.B. Saunders, 2001: 457–474.
- Bruzinska-Schmidhalter R, Nett-Mettler CS. Spontaneous remission in canine generalized demodicosis – predisposing factors. *Veterinary Dermatology* 2011; 22: 301 (Abstract).
- Fondati A. Efficacy of daily oral ivermectin in the treatment of 10 cases of generalized demodicosis. *Veterinary Dermatology* 1996; 7: 99–104.
- Mueller RS, Meyer D, Besignor E *et al.* Treatment of canine generalized demodicosis with a 'spot-on' formulation containing 10% moxidectin and 2.5% imidacloprid (Advocate®, Bayer Healthcare). *Veterinary Dermatology* 2009; 20: 441–446.
- Mueller RS, Bettenay SV. Skin scrapings and skin biopsies. In: Ettinger SJ, Feldman EC, eds. *Textbook of Veterinary Internal Medicine*. Philadelphia, W.B. Saunders, 2010; 368–371.
- Beco L, Fontaine F, Bergvall K *et al.* Comparison of skin scrapes and hair plucks for detecting *Demodex* mites in canine demodicosis, a multicentre, prospective study. *Veterinary Dermatology*, 2007; 18: 381 (Abstract).
- Besignor E. Comparaison de trois techniques diagnostiques de demodecie a *Demodex canis* chez le chien. *Pratique Medicale and Chirurgicale de l'Animal de Compagnie* 2003; 38: 167–171.
- Fondati A, De Lucia M, Furiani N *et al.* Prevalence of *Demodex canis*-positive healthy dogs at trichoscopic examination. *Veterinary Dermatology* 2010; 21: 146–151.
- Kwochka KW, Kowalski JJ. Prophylactic efficacy of four antibacterial shampoos against *Staphylococcus intermedius* in dogs. *American Journal of Veterinary Research* 1991; 52: 115–118.
- Mueller RS. Topical dermatological therapy. In: Maddison JE, Page SW, Church DB, eds. *Small Animal Pharmacology*. Philadelphia, W.B. Saunders, 2008; 546–556.

37. Hugnet C, Bruchon-Hugnet C, Royer H *et al.* Efficacy of 1.25% amitraz solution in the treatment of generalized demodicosis (eight cases) and sarcoptic mange (five cases) in dogs. *Veterinary Dermatology* 2001; 12: 89–92.
38. Kwochka KW, Kunkle GA, Foil CS. The efficacy of amitraz for generalized demodicosis in dogs: a study of two concentrations and frequencies of application. *The Compendium on Continuing Education for the Practising Veterinarian* 1985; 7: 8–17.
39. Medleau L, Willemse T. Efficacy of daily amitraz therapy for refractory, generalized demodicosis in dogs: two independent studies. *Journal of the American Animal Hospital Association* 1995; 31: 246–249.
40. Muller GH. Amitraz treatment of demodicosis. *Journal of the American Animal Hospital Association* 1983; 19: 435–441.
41. Mueller RS, Bettenay SV. Milbemycin oxime in the treatment of canine demodicosis. *Australian Veterinary Practitioner* 1995; 25: 122–126.
42. Fourie LJ, Kok DJ, du Plessis A *et al.* Efficacy of a novel formulation of metaflumizone plus amitraz for the treatment of demodectic mange in dogs. *Veterinary Parasitology* 2007; 150: 268–274.
43. Rosenkrantz W. Efficacy of metaflumizone plus amitraz for the treatment of juvenile and adult onset demodicosis in dogs: pilot study of 24 dogs. *Veterinary Dermatology* 2009; 20: 227 (Abstract).
44. Oberkirchner U, Linder K, Dunston S *et al.* Metaflumizone–amitraz (Promeris)-associated pustular acantholytic dermatitis in 22 dogs: evidence suggests contact drug-triggered pemphigus foliaceus. *Veterinary Dermatology* 2011; 22: 436–448.
45. Holm BR. Efficacy of milbemycin oxime in the treatment of canine generalized demodicosis: a retrospective study of 99 dogs (1995–2000). *Veterinary Dermatology* 2003; 14: 189–195.
46. Sasaki Y, Kitagawa H, Murase S. Susceptibility of rough-coated collies to milbemycin oxime. *Japanese Journal of Veterinary Science* 1990; 52: 1269–1271.
47. Barbet JL, Snook T, Gay JM *et al.* ABCB1-1Δ (MDR1-1Δ) genotype is associated with adverse reactions in dogs treated with milbemycin oxime for generalized demodicosis. *Veterinary Dermatology* 2009; 20: 111–114.
48. Scott DW, Walton DK. Experiences with the use of amitraz and ivermectin for the treatment of generalized demodicosis in dogs. *Journal of the American Animal Hospital Association* 1985; 21: 535–541.
49. Ristic Z, Medleau L, Paradis M *et al.* Ivermectin for treatment of generalized demodicosis in dogs. *Journal of the American Veterinary Medical Association* 1995; 207: 1308–1310.
50. Guaguere E. Traitement de la demodecose generalisee du chien par l'ivermectine: a propos de 20 cas. *Pratique Medicale et Chirurgicale de l'Animal de Compagnie* 1996; 31: 31–40.
51. Medleau L, Ristic Z, McElveen DR. Daily ivermectin for the treatment of generalized demodicosis in dogs. *Veterinary Dermatology* 1996; 7: 209–212.
52. Mueller RS, Hastie K, Bettenay SV. Daily oral ivermectin for the treatment of generalised demodicosis in 23 dogs. *Australian Veterinary Practitioner* 1999; 29: 132–136.
53. Delayte EH, Otsuka M, Larsson CE *et al.* Efficacy of systemic macrocyclic lactones (ivermectin and moxidectin) for the treatment of generalized canine demodicosis. *Arquivo Brasileiro de Medicina Veterinária e Zootecnia* 2006; 58: 31–38.
54. Mueller RS, Bettenay SV. A proposed new therapeutic protocol for the treatment of canine mange with ivermectin. *Journal of the American Animal Hospital Association* 1999; 35: 77–80.
55. Hugnet C, Lespine A, Alvinerie M. Multiple oral dosing of ketoconazole increases dog exposure to ivermectin. *Journal of Pharmacy and Pharmaceutical Sciences* 2007; 10: 311–318.
56. Mayer UK, Glos K, Schmid M *et al.* Adverse effects of ketoconazole in dogs – a retrospective study. *Veterinary Dermatology* 2008; 19: 199–208.
57. Mealey KL, Bentjen SA, Gay JM *et al.* Ivermectin sensitivity in collies is associated with a deletion mutation of the *mdr1* gene. *Pharmacogenetics* 2001; 11: 727–733.
58. Mealey KL, Meurs KM. Breed distribution of the ABCB1-1Δ (multidrug sensitivity) polymorphism among dogs undergoing ABCB1 genotyping. *Journal of the American Veterinary Medical Association* 2008; 233: 921–924.
59. Roulet A, Puel O, Gesta S *et al.* MDR1-deficient genotype in Collie dogs hypersensitive to the P-glycoprotein substrate ivermectin. *European Journal of Pharmacology* 2003; 460: 85–91.
60. Bissonnette S, Paradis M, Daneau I *et al.* The ABCB1-1Δ mutation is not responsible for subchronic neurotoxicity seen in dogs of non-collie breeds following macrocyclic lactone treatment for generalized demodicosis. *Veterinary Dermatology* 2009; 20: 60–66.
61. Besignor E, Carlotti D. Moxidectin in the treatment of generalized demodicosis in dogs. A pilot study: 8 cases. In: Kwochka KW, Willemse T, Von Tscharner C, eds. *Advances in Veterinary Dermatology*. Oxford, Butterworth-Heinemann, 1998; 554–555.
62. Burrows A. Evaluation of the clinical efficacy of two different doses of moxidectin in the treatment of generalized demodicosis in the dog. Annual Meeting of the Australian College of Veterinary Scientists, Goold Coast, Australia, 1997.
63. Wagner R, Wendlberger U. Field efficacy of moxidectin in dogs and rabbits naturally infested with *Sarcoptes* spp., *Demodex* spp. and *Psoroptes* spp. mites. *Veterinary Parasitology* 2000; 93: 149–158.
64. Heine J, Krieger K, Dumont P *et al.* Evaluation of the efficacy and safety of imidacloprid 10% plus moxidectin 2.5% spot-on in the treatment of generalized demodicosis in dogs: results of a European field study. *Parasitological Research* 2005; 97(Suppl 1): S89–S96.
65. Fourie JJ, Delpont PC, Fourie LJ *et al.* Comparative efficacy and safety of two treatment regimens with a topically applied combination of imidacloprid and moxidectin (Advocate®) against generalised demodicosis in dogs. *Parasitological Research* 2009; 105(Suppl 1): S115–S124.
66. Johnstone IP. Doramectin as a treatment for canine and feline demodicosis. *Australian Veterinary Practitioner* 2002; 32: 98–103.
67. Murayama N, Shibata K, Nagata M. Efficacy of weekly oral doramectin treatment in canine demodicosis. *Veterinary Record* 2010; 167: 63–64.
68. Schnieder T, Kordes S, Epe C *et al.* Investigations into the prevention of neonatal *Toxocara canis* infections in puppies by application of doramectin to the bitch. *Zentralblatt für Veterinärmedizin. Reihe B* 1996; 43: 35–43.
69. Schnieder T, Lechler M, Epe C *et al.* The efficacy of doramectin on arrested larvae of *Ancylostoma caninum* in early pregnancy of bitches. *Zentralblatt für Veterinärmedizin. Reihe B* 1996; 43: 351–356.
70. Lavy E, Aroch I, Bark H *et al.* Evaluation of doramectin for the treatment of experimental canine spirocerosis. *Veterinary Parasitology* 2002; 109: 65–73.
71. Yas-Natan E, Shamir M, Kleinbart S *et al.* Doramectin toxicity in a collie. *Veterinary Record* 2003; 153: 718–720.
72. Geyer J, Klintzsch S, Meerkamp K *et al.* Detection of the nt230(del4) MDR1 mutation in White Swiss Shepherd dogs: case reports of doramectin toxicosis, breed predisposition, and microsatellite analysis. *Journal of Veterinary Pharmacology and Therapeutics* 2007; 30: 482–485.
73. Miller WH Jr, Wellington JR, Scott DW. Dermatologic disorders of Chinese Shar Peis: 58 cases (1981–1989). *Journal of the American Veterinary Medical Association* 1992; 200: 986–990.
74. Hamann F, Wedell H, Bauer J. Zur Demodikose des Hundes. *Kleintierpraxis* 1997; 42: 745–754.
75. Folz SD, Kratzer DD, Conklin RD *et al.* Chemotherapeutic treatment of naturally acquired generalized demodicosis. *Veterinary Parasitology* 1983; 13: 85–93.
76. Anon. Dermatologists recommend neutering of canine patients with demodicosis. *Journal of the American Veterinary Medical Association* 1983; 182: 1048.

Appendix 1: Summarized treatment of canine demodicosis

Treatment of a dog with localized and mild to moderate disease

- 1 Use topical therapy with chlorhexidine or benzoyl peroxide shampoo weekly.
- 2 Monitor the disease progression. Many dogs will show resolution of clinical signs. Dogs with deteriorating disease should be treated as described below.

Treatment of a dog with severe generalized disease

- 1 Perform cytology and (with evidence of secondary bacterial skin infection) ideally a bacterial culture and sensitivity. With inflammatory cells and bacteria present, appropriate oral antibiotic therapy is recommended.
- 2 Use topical therapy with chlorhexidine or benzoyl peroxide shampoo weekly to possibly twice weekly.
- 3 Several options exist for the treatment of the *Demodex* mites and which option is best will depend on the legalities pertaining to the use of veterinary pharmaceutical products in the country of residence, the finances of the owner and the clinical situation. However, independent of the treatment specifics the dog should be neutered because dogs in need of mite treatment should not be allowed to breed, and the disease may relapse in cycling bitches.
 - a Amitraz weekly or every 2 weeks in a concentration of 0.025–0.06% can be used. Dogs with a mid to long hair coat need to be clipped, and skin should stay dry between rinses to avoid washing off the drug. Rinsing should be performed in well-ventilated areas.
 - b Milbemycin oxime may be administered orally at a dose of 1–2 mg/kg/day.
 - c Moxidectin as a spot-on in combination with imidacloprid may be used weekly. This spot-on formulation has a markedly higher success rate in dogs with milder disease.
 - d Ivermectin at a dose of 0.3–0.6 mg/kg or moxidectin at 0.2–0.5 mg/kg p.o. daily are further options. With both drugs, a gradual increase from an initial dose of 0.05 mg/kg to the final dose within a few days is recommended to identify dogs that cannot tolerate those drugs. Monitoring for neurological adverse effects should occur throughout the course of therapy.
 - e Doramectin weekly at 0.6 mg/kg p.o. or s.c. is a possible treatment. A gradual increase from an initial dose of 0.1 mg/kg to the final dose seems prudent to identify dogs that cannot tolerate the drug and will show neurological adverse effects.
 - f Dogs should be evaluated monthly, and treatment should be continued beyond negative skin scrapings.
 - g Factors predisposing to demodicosis, such as malnutrition, endoparasites, endocrine disease, neoplasias and chemotherapy, should be identified and corrected to maximize response to therapy.

Résumé La démodécie canine est fréquente en pratique des petits animaux et il existe un certain nombre de traitements possible. Ces recommandations ont été écrites par un groupe international de spécialistes avec l'objectif de les fournir aux vétérinaires pour le diagnostic et le traitement de cette maladie. Les études publiées sur les différentes options de traitement ont été examinées et résumées. Lorsque les preuves n'étaient pas disponibles pour certaines publications, un consensus d'experts formait la base des recommandations. La démodécie est généralement diagnostiquée par raclages cutanés profonds ou par trichogrammes ; dans de rares cas une biopsie cutanée peut être requise. Les facteurs compromettants le système immunitaire, tels que l'endoparasitisme ou la malnutrition chez les jeunes chiens, les dysendocrinies, les tumeurs et la chimiothérapie chez les vieux chiens, sont considérés comme des facteurs prédisposants et devraient être diagnostiqués et traités afin d'optimiser les résultats thérapeutiques. Les chiens dont la sévérité de la maladie nécessite un traitement antiparasitaire ne devraient pas être reproduits. Les infections bactériennes cutanées secondaires compliquent fréquemment la maladie et nécessitent un traitement antimicrobien topique et/ou systémique. Dans le traitement de la démodécie canine, le niveau de preuve est bon concernant l'efficacité de bains hebdomadaires d' amitraz à 250–500 p.p.m. et l'administration orale quotidienne de lactones macrocycliques telles que la milbémycine oxime à 1–2 mg/kg, l'ivermectine à 0.3–0.6 mg/kg et la moxidectine à 0.2–0.4 mg/kg. L'application hebdomadaire de moxidectine topique peut être utile chez les chiens présentant une forme modérée de la maladie. Il existe certaines preuves de l'efficacité de la doramectine sous-cutanée ou orale, hebdomadaire ou bihebdomadaire à 0.6 mg/kg. Les lactones macrocycliques systémiques peuvent engendrer des effets secondaires neurologiques chez les chiens sensibles ; il serait prudent d'augmenter la dose progressivement jusqu'à la dose finale thérapeutique (en particulier chez les bergers) afin de mettre en évidence les chiens ne tolérant pas ces molécules. Le traitement doit être contrôlé par des raclages cutanés mensuels et doit être prolongé au delà de la guérison clinique et microscopique afin de minimiser les récives.

Resumen La demodicosis canina es frecuente en las consultas de pequeños animales y existen varias terapias posibles. Estas directrices han sido escritas por un grupo internacional de especialistas con el propósito de proporcionar a los veterinarios las recomendaciones más actuales para el diagnóstico y el tratamiento de esta enfermedad. Se revisaron y resumieron los estudios publicados donde se exponían diversas opciones de tratamiento. En los casos en que no había clara evidencia del tratamiento en forma de estudios publicados, la base de las recomendaciones fue el consenso de los expertos. La demodicosis puede ser generalmente diagnosticada mediante raspados profundos de la piel o en tricogramas; y en casos raros una biopsia de la piel podría ser necesaria para el diagnóstico. Factores que comprometen el sistema inmune, tal como el endoparasitismo o la malnutrición en perros jóvenes y enfermedades endocrinas, neoplasia y quimioterapia en perros más viejos, se consideran elementos que favorecen la infección y se deben diagnosticar y tratar para optimizar el resultado terapéutico. Los perros con enfermedad severa que requiere terapia parasiticida no deben ser utilizados con propósito de cría. Las infecciones bacterianas secundarias en la piel complican la enfermedad y requieren con frecuencia terapia antimicrobiana tópica y/o sistémica. Hay clara evidencia al respecto de la eficacia de los lavados semanales con amitraz a 250–500 p.p.m. y del tratamiento diario con lactonas macrocíclicas orales tales como la oxima de milbemicina a 1–2 mg/kg, la ivermectina a 0.3–0.6 mg/kg y la moxidectina a 0.2–0.4 mg/kg para el tratamiento de la demodicosis canina. El uso semanal de moxidectin por vía tópica puede ser útil en perros con formas más leves de la enfermedad. Hay cierta evidencia relativa a la eficacia del semanal o dos veces en semana de doramectina subcutánea u oral a dosis de 0.6 mg/kg. Las lactonas macrocíclicas por vía sistémica pueden causar efectos nocivos neurológicos en perros sensibles, por lo que un aumento gradual hasta la dosis terapéutica final podría ser prudente (particularmente en razas de perros pastores) para identificar con prontitud los perros que no toleran esos fármacos. El tratamiento se debe supervisar con raspados mensuales de la piel y debe extenderse pasada la curación clínica y microscópica para reducir al mínimo las recidivas.

Zusammenfassung Die canine Demodikose ist eine häufige Erkrankung in der Kleintierpraxis mit mehreren Therapiemöglichkeiten. Diese Richtlinien wurden von einer internationalen Gruppe von Spezialisten mit dem Ziel, TierärztInnen die momentanen Empfehlungen zur Diagnose und zur Therapie der Erkrankung zur Verfügung zu stellen, geschrieben. Die publizierten Studien der unterschiedlichen Behandlungsmethoden wurden 'reviewed' und zusammengefasst. Wo keine Evidenz in Form von publizierten Studien bestand, wurde der Consensus der ExpertInnen als Basis für die Empfehlungen herangezogen. Die canine Demodikose kann normalerweise mittels tiefer Hautgeschabsel oder Trichogramm diagnostiziert werden; in seltenen Fällen ist für die Diagnose eine Hautbiopsie nötig. Faktoren, die das Immunsystem beeinträchtigen, wie Endoparasiten oder schlechte Ernährung bei Junghunden, sowie endokrine Erkrankungen, Neoplasien und Chemotherapie bei älteren Hunden werden als prädisponierende Faktoren angesehen und sollten diagnostiziert und behandelt werden, um den Therapieerfolg zu optimieren. Mit Hunden, die die Erkrankung in einem Schweregrad aufweisen, die eine Therapie mit Antiparasitika notwendig macht, sollte nicht gezüchtet werden. Sekundäre bakterielle Infektionen verkomplizieren häufig die Erkrankung und erfordern eine topische und/oder systemische antimikrobielle Behandlung. Es besteht eine gute Evidenz für die Wirksamkeit von wöchentlichen Amitraz Bädern in einer Dosierung von 250–500 p.p.m. und tägli-

che orale Verabreichung von makrozyklischen Laktone, wie Milbemycinoxim in einer Dosierung von 1–2 mg/kg, Ivermectin in einer Dosierung von 0.3–0.6 mg/kg und Moxidectin in einer Dosierung von 0.2–0.4 mg/kg zur Behandlung der caninen Demosikose. Eine wöchentliche topische Verabreichung von Moxidectin kann bei Hunden mit einer weniger stark ausgeprägten Erkrankung hilfreich sein. Teilweise besteht Evidenz für die Wirksamkeit wöchentlicher oder zweimal wöchentlicher subkutaner oder oraler Verabreichung von Doramectin in einer Dosierung von 0.6 mg/kg. Systemisch verabreichte makrozyklische Laktone können bei empfänglichen Hunden neurologische Nebenwirkungen verursachen, daher ist als Vorsichtsmaßnahme ein gradueller Anstieg der Dosierung bis zur letztendlich verabreichten Dosis (vor allem bei Herdenhunden) sinnvoll, um jene Hunde zu identifizieren, die diese Wirkstoffe eventuell nicht tolerieren können. Die Behandlung sollte monatlich durch Hautgeschabsel kontrolliert werden und um Rückfälle zu vermeiden, über eine klinische sowie eine mikroskopische Heilung hinaus gegeben werden.

要約 背景と目的 犬の毛包虫症は一般的な疾患であり、治療には様々な方法が行われてきた。本ガイドラインは専門医の国際的なグループが、この疾患の診断と治療についての最近の動向を、獣医師に提供する目的で作成した。方法 多数の治療オプションについてすでに公表されている研究結果を検討し、要約した。公表された形でエビデンスが得られていない場合は、専門家の意見を動向の元とした。結果 毛包虫症は深い皮膚掻爬検査、または被毛の鏡検で通常診断が可能である；稀に診断に皮膚生検が必要なことがある。若齢犬での内部寄生虫症や栄養不良、老齢犬での内分泌疾患、腫瘍や化学療法などの免疫システムを障害する要因は、治療成績を向上させるために診断、治療する。疾患が重度で殺寄生虫治療が必要な犬は繁殖させない。二次的な細菌性皮膚感染症はしばしば疾患を複雑にし、局所あるいは／および全身的な抗菌剤治療が必要である。250–500 ppm のアミトラズを用いた週に1回の薬浴、1–2 mg/kg のミルベマイシンオキシム、0.3–0.6 mg/kg のイバルメクチン、0.2–0.4 mg/kg のモキシデクチンなどの大環状ラクトンの連日経口投与は、犬の毛包虫症の治療に有効であるという十分なエビデンスがあった。週に1回のモキシデクチンの外用は症状が軽度の犬で有用であった。週に1回、または2回の0.6 mg/kg ドラメクチンの皮下または経口投与の有効性には多少のエビデンスがあった。大環状ラクトンの全身的な投与に感受性のある犬は神経系の副作用を示すことがある。したがって、これらの薬物に対する耐性を確認するために（特に牧畜犬種で）、最終的な治療用量に達するまで、段階的に用量を増加させることが賢明である。毎月皮膚掻爬検査でモニターを行い、再発を最低限に押さえるために臨床的、顕微鏡的に治癒するまで治療を行う。

摘要

背景及目的 - 是由国际专家团队撰写的指南，目的是为兽医推荐当前使用的犬蠕形螨病的诊断及治疗方案。

方法 - 回顾和总结过去发表的各种治疗方案。各种推荐方案是建立在专家共识的基础之上的，在此不再赘言过去的研究依据。

结果 - 蠕形螨病常可通过皮肤深刮或拔毛诊断；少数病例的诊断可能需要皮肤活检。

幼犬的内寄生虫或营养不良，以及老年犬的内分泌疾病、肿瘤和化疗都是导致免疫抑制的原因，也是蠕形螨病的易感因素，同时诊断和治疗上述疾病才能达到理想的效果。病情严重的犬需要驱虫治疗且不应进行繁殖。

继发细菌性皮肤感染经常使蠕形螨病更加恶化，需要局部和/或全身的抗生素治疗。

证据表明，每周双甲脒浸泡和每日使用大环内酯类如米尔倍肟、伊维菌素和莫西克丁治疗犬蠕形螨病，可以达到很好的效果。每周外部使用莫西克丁对病情较轻的患犬有效。一些证据表明每周一次或每周两次多拉菌素皮下注射或口服有效。全身使用大环内酯类药物可能导致敏感犬发生神经性的副反应，因此需要谨慎地逐渐增加治疗剂量（特别是对于牧羊犬种）。

每月通过皮肤深刮进行监测，为了减少复发，当临床与显微镜检查都为阴性时，治疗还需再延续一段时间。