

Transconjunctival/Subconjunctival Enucleation

The transconjunctival approach involves an initial incision around the bulbar conjunctiva and has the advantages of reduced orbital tissue loss and subsequent orbital sinking with time, less haemorrhaging intraoperatively, and a faster procedure time. This approach should not be used in a patient with a suspected or known intraocular infection. It is important to identify and remove all conjunctival tissue and nictitating membrane with glands to avoid the postoperative complications.

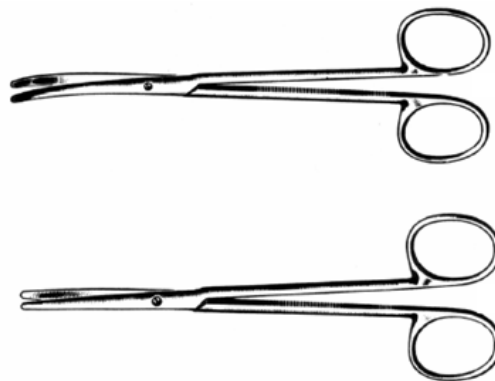
- Usually used for non-contaminated cases
- The eyelid remains open

A transconjunctival enucleation is completed with forceps and scissors exclusively.

1) A lateral canthotomy is done - The entire thickness of the eyelid at the lateral canthus is incised with scissors, but do not cut the lateral orbital ligament. An eyelid speculum in the eye at the time of the canthotomy will make this easier.

2) Grasp the bulbar conjunctiva and incised 360 degrees around the globe leaving at least 5 mm attached to the globe for manipulation.

3) The conjunctiva not attached to the globe is undermined with curved scissors (preferably Metzenbaum scissors - below), and the attachments of the extraocular muscles (and other tissue), to the globe are severed. This dissection is carried out until the globe is freed enough to rotate within the orbit.



4) A clamp (curved hemostat- below, or tonsil snare), is placed around the optic nerve and associated blood vessels. Curved scissors are used to sever the final attachments distal to the clamp, and the eye is removed and placed in appropriate fixative prior to submitting it for histologic evaluation.



5) Absorbable suture material may be used in an attempt to place a ligature proximal to the clamp, and the clamp removed; realistically, you may simply leave the clamp in place for several minutes for hemostasis, and not use a ligature.

6) The nictitating membrane then is excised (if it was not removed along with the globe) along with the remainder of the bulbar and palpebral conjunctiva.

7) Absorbable suture material is used to appose the subconjunctival tissues across the orbit.

8) The eyelid margins (about the distal 3 mm), are removed around the entire circumference (exercise extra care medially: here it is more difficult to adequately excise the tissue; you must remove all skin, the caruncle, and the medial canthal ligament; if not adequately excised, healing will be impaired). The incised edge of the upper eyelid then is apposed to the lower using non-absorbable skin suture in an interrupted fashion (either simple or horizontal mattress).

*Note – Side Effects

1) For a few days after surgery, there may be a bloody discharge from the nostril on the side of the surgery due to passage down the nasolacrimal duct. The client should be told about this.

2) Regardless of how the surgery is done, there usually is a certain amount of permanent invagination of the skin overlying the orbit after healing occurs; the client must be warned about this. Fortunately, with time, regrowth of hair helps improve the appearance.

3) On occasion, glandular secretions (conjunctival or lacrimal), may persist after surgery so that a fluid-filled cyst forms. This easily is corrected by re-entering the orbit and dissecting out the cyst.